PROCEEDINGS

The First Congress of

SEAVSA

(South East Asia Veterinary School Association)

Animal Health & Production for Better ASEAN Quality of Life

Challenge of Veterinary Education

IPB International Convention Centre
Bogor, Indonesia July 20 - 22 2010

Organizing Committee
Faculty of Veterinary Medicine, Bogor Agricultural University (IPB)
Jl. Agatis, Kampus IPB Darmaga Bogor 16680, INDONESIA
Phone: +62-251-8628080, +62-251-8628181; Fax: +62-251-8628181
E-mail : conferenceipb2010@gmail.com; Website : http://fkh.ipb.ac.id/index.php/seavsa

FOREWORD

World Organization of Animal Health (OIE) held an international conference among Dean of veterinary school in Paris, on October 2009. One of the results of the conference was to recommend that every nation or region constitute an institution of veterinary certification devoted in improving the integrity and collaboration among the nations in a region. Refer to the recommendation, veterinary school in South East Asia found an association called "South East Asia Veterinary School Association-SEAVSA". This association declared on 7 December 2009 in Putra Jaya Malaysia.

To initiate global challenge in veterinary perspective, the SEAVSA successfully recognized their essential influences in improving veterinary services and contributing to the world. Throughout a comprehensive collaboration among veterinary school across South East Asia region, this organization conducted a congress. Faculty of Veterinary Medicine, Bogor Agricultural University has the honor to hold the first agenda of SEAVSA, the First Congress of SEAVSA "Animal Health and Production for Better ASEAN Quality of Life - Challenge of Veterinary Education". Four main topics related to the main theme are veterinary education and profession, biodiversity and biomedical reserach, public health, zoonoses and food safety, anima health, ecohealth and animal production.

From this congress, we have achieving veterinarians, professional, and researcher from related field to communicate their ideas and wealth of knowledge and proposing emerging issues through scientific papers compiled in this proceeding.

Finally, from this congress we hope that SEAVSA can improves their integrity in understanding the new scope of activities and obligations facing them, and collectively embrace a common theme or central discipline that unifies the profession to and create an identify for the public they serve.

Editors

July, 2010

The 1st Congress of South East Asia Veterinary School Association

	Plennary Sessions	**Page**
OPS 1	South East Asia Veterinary School Association (SEAVSA): Roles and Direction in Veterinary Education *Prof. Bashir Ahmad Fateh Mohamed* *President of SEAVSA* *Dean of Faculty of Veterinary Medicine, University Putra Malaysia*	1
OPS 2	a. The Contribution of Veterinary Education to the Improvement of Veterinary Education Quality in ASEAN Countries b. Para rubber model: New trend for medical practice *Prof. Apinun Suprasert* *Vice Dean Faculty of Veterinary Medicine, Kasetsart University, Thailand*	4
OPS 3	Relevance of OIE to Veterinary Education *Dr. Gardner Murray* *OIE Sub-Regional Representative for South East Asia*	9
OPS 4	Development and Addressing the Problems of Animal Production: A Challenge to the Veterinarian *Prof. Conrado A. Valdez* *Dean College of Veterinary Medicine University of the Philippines Los Baños*	10
OPS 5	Animal Health and Veterinary Legislation in Indonesia *Dr. Agus Wiyono* *Director of Animal Healt, Directorate General of Livestock Services and Animal Health, Ministry of Agriculture, Indonesia*	14
OPS 6	OIE Programme on Strengthening Veterinary Governance and Legislation in South East Asia *Dr. Ronello Abilla* *OIE Sub-Regional Representative for South East Asia*	18
OPS 7	Bio-Diversity in Indonesia: The Sleeping Giant *Dr. I Wayan Teguh Wibawan, MS* *Dean Faculty of Veterinary Medicine, Bogor Agricultural University (IPB), Indonesia*	19
OPS 8	Zoonoses, Public Health, and Veterinary Education in Vietnam *Prof. Tran Duc Vien* *Rector Hanoi University of Agriculture, Ha Noi, Vietnam*	21
OPS 9	One Health: How Veterinary Education Moves on? *Prof. Parntep Ratanakorn* *Vice Dean Faculty of Veterinary Science, Mahidol University, Thailand*	23

	ORAL PRESENTATION	**Page**
	Veterinary Education and Profession	
OVEP 1	Application of the Multimedia Equipments to Encourage the Students in Studying Veterinary Anatomy *Hery Wijayanto*	29
OVEP 2	Qualitative Assessment of the Need for Veterinary Public Health Education in Indonesia *Iwan Willyanto, Joann M. Lindenmayer*	31
OVEP 3	Quantitative Assessment of the Need for Veterinary Public Health Education in Indonesia *Joann M. Lindenmayer, Iwan Willyanto*	33
OVEP 4	Impact of Intensive Livestock on Animal Heath, Human Heath, and Environment: New Idea of Current Need of Educational and Research Programs in Vietnam *Tien Dam Van*	35
OVEP 5	Development of Graduate's Soft Skills Competencies in the Faculty of Veterinery Medicine, Bogor Agricultural University (IPB) *Srihadi Agungpriyono, Nastiti Kusumorini*	37
OVEP 6		38
OVEP 7	Academic Leadership: Turning Vision Into Reality *Sheikh Omar Abdul Rahman*	39

	Biodiversity and Biomedical Research	**Page**
OBBR 1	Naturally Occurring Gastric Cryptosporidiosis in the Laboratory Mice *Dewi Ratih Agungpriyono, Sri Estuningsih, Hernomoadi Huminto*	43
OBBR 2	Antibody Responses to Avian Influenza Vaccination in Broiler Chickens in Indonesia *Erianto Nugroho, Retno D. Soejoedono, Trioso Purnawarman, Chaerul Basri, P. Hermas, A.T Muljono, A.J Nell*	45
OBBR 3	Quality Control of Infectious Bursal Disease Vaccines Tested at NVDAL-Indonesia *Ida Lestari Soedijar, Bahruddin Syahroni*	47
OBBR 4	Effect on Java Ginseng Extract (*Talinum pariculatum Gaertn*) on Hyperglycemia rats (Sprague Dawley) *Ietje Wientarsih, Sila Sakti, Norman Razief A.*	49

OBBR 5	*In Vitro* Differentiation of Adult Rat Bone Marrow Stromal Cells Into Neurons Using Condition Medium of Newborn Rat Neuron Primary Culture *Ita Djuwita, Kusdiantoro Mohamad, Wahono Esthi Prasetyaningtyas, Nurhidayat*	51
OBBR 6	Seroepidemiology of Dengue and Chikungunya Viruses at Several Outdoor Breeding Facilities of Nonhuman Primates in West Java, Indonesia *Joko Pamungkas, Rachmitasari Noviana, Diah Iskandriati, Dondin Sajuthi, I Nengah Budiarsa*	53
OBBR 7	Feed Consumption, Body Weight, and Body Mass Index in Obes Male Long-Tailed Macaque (*Macaca fascicularis*) Which Nicotine Intervetion *L. M. Saniwu, A. Suprayogi, S. S. Mansjoer*	55
OBBR 8	Serum Level of FSH and Degree of Infertility on Inhibin B 32 kDa Induced Rats *Muslim Akmal, Aulanni'am, M Aris Widodo, Sutiman B Sumitro, Basuki Bambang Purnomo*	58
OBBR 9	Effect of Inhibin B on Motility of Rat Sperm: A Development of Peptide Male Hormonal Contraception *Aulanni'am, Gatot Ciptadi, Chanif Mahdi, Muslim Akmal*	61
OBBR 10	Level of Corticosterone Associated with Diabetic Rat Models *Pudji Astuti, Mulyati Sarto, Laksmindra Fitria, Sismindari Sudjadi*	64
OBBR 11	Preimplantation Development of Activated Mouse Oocytes by Treatment with Trichostatin A and Scriptaid in the Activation Medium *Harry Murti, M. Fahrudin, Arief Boediono, Boenjamin Setiawan, Ferry Sandra*	66
OBBR 12	Adhesin of *Chlamydia pneumoniae* Associated to Rupture of Atherosclerotic Plaques by Degradation of Collagen Type-IV *In Vitro* *Sri Murwani*	68
OBBR 13	Profile of Blood Total Protein and Lipid in Rats (*Rattus norvegicus*) Which Contract Enteritidis Treated with Goat's Milk Peptide *Retno SW, Anwar M, Romziah S*	72
OBBR 14	The Use of Recombinant Granule Protein-1 for Seroprevalency of Toxoplasmosis in Animal and Human *Wayan T Artama, Sumartono, Sujono, Mahardika*	74
OBBR 15	Growth Potential of Mouse Stem Cells Produced from Embryos at Cleavage, Morula and Blastocyst Stages *Thomas Mata Hine, Iman Supriatna, Dondin Sajuthi, Arief Boediono*	77

OBBR 16	Development of Catecholaminergic Neurons in the Medulla Oblongata of Long-tailed Macaque (*Macaca fascicularis*): An Immunohistochemical Study *Tri Wahyu Pangestiningsih, Koeswinarning S Sigit, Dondin Sajuthi, Nurhidayat, Douglas M*	79
OBBR 17	Maladies In Exotic Aquatic Animals *Hassan Hj Mohd Daud*	81

	Public Health, Zoonosis and Food Safety	**Page**
OPZF 1	Seasonal Impact on Highly Pathogenic Avian Influenza (HPAI) Cases in Chickens Coming to Poultry Collecting Facilities (PCFS) in Jakarta *Andri Jatikusumah, Chaerul Basri, Sunandar, Deswarni, D. Hidjah*	85
OPZF 2	Biosecurity Practices in Village Poultry in Cipunagara SubDistrict, Subang Distric, West Java: a Cross-sectional Survey *Denny Widaya Lukman, Y Ridwan, BA Wibowo, AZ Ilyas, C Basri, E Sudarnika, A Sugama, P Hermans, AJ Nell*	87
OPZF 3	Live Performance of Crossbred Kampong Chickens Reared Over Different Market Ages *Engku Azahan E. A., Azlina Azma I. A, Noraziah M*	89
OPZF 4	Cost-Effectiveness Analysis of Rabies Control On Flores Island *Ewaldus Wera, Marieke Opsteegh*	91
OPZF 5	Protection and Promotion of Public Health through Animal Health *Saleha A. A.*	93
OPZF 6	Avian Influenza Detection in Incoming Chickens and the Environment of Poultry Collecting Facilities (PCFS) in DKI Jakarta *Sunandar, A.T Muljono, C. Basri, Andri Jatikusumah, R. Yuswari, D. Hidjah*	96
OPZF 7	Vaccination of Broilers Against Highly Pathogenic Avian Influenza H5N1 Does Not Reduce Virus Transmission *O. N. Poetri, A. Bouma, I. Claassen, G. Koch, R.D Soejoedono, J.A. Stegeman, Michiel van Bohen*	98

	Animal Health, Ecohealth and Animal Production	**Page**
OAEA 1	Surface Character of Coagulase-Positive and Coagulase-Negative of *Staphylococcus aureus* Isolated from Origin Goat's Milk That Contribute in Adhesion to Mammary Epithelial Cells *Agnesia Endang Tri Hastuti Wahyuni, M. H. Wibowo, Franky, B. B. Ajiguno*	101

OAEA 2	Detection of *Streptococcus aglactiae* Infected to Mouse Mammary Gland as a Model for Bovine Subclinical Mastitis *Sri Estuningsih*	103
OAEA 3	Study Protectivity of Immunoglobulin Y (Ig-Y) Against *Aeromonas hydrophila* in Carp Fish (*Cyprinus caprio* L.) *Rahmat Hidayat*	105
OAEA 4	Blood Profile of Rats (*Rattus norvegicus*) Contract Lung Cancer Treated with Goat's Milk Peptide *Anwar Ma'ruf, Retno Sri Wahjuni, Romziah S*	107
OAEA 5	Study on Viral Inactivation Capability of Aquaoasis Against H5N1 Avian Influenza Virus *Sri Murtini, Retno D. Soejodono, Usamah Afiff, Titiek Sunartatie*	109
OAEA 6	Anti Avian Influenza Nutritional Food as Solution for Medication of Avian Influenza Disease in Human *Retno D. Soejodono, Sri Murtini, I Wayan T Wibawan*	111
OAEA 7	Identification of Gastrointestinal Worms from Egg Fecal Samples of Bawean Deer (*Axis kuhlii*) in Surabaya Zoological Garden *Setiawan Koesdarto, Ahmad Hunaifi, Hario Puntodewo Siswanto, Endang Suprihati*	113
OAEA 8	Evaluation of Behavioral Changes for Pain Assessment in Sheep *Ling CY, Chen Hui Cheng, Sumita S*	115
OAEA 9	Preservation, Isolation and Developmental Competence *In Vitro* of Ovine Preantral Follicles *Bayu Rosadi, M. Agus Setiadi, Dondin Sajuthi, Arief Boediono*	117
OAEA 10	Intracytoplasmic Sperm Injection (ICSI) Using Motile and Immotile Sperm Extracted from Preserved Ram Epididymal *Sigit Prastowo, M. Agus Setiadi, Arief Boediono*	119
OAEA 11	Estrous Characteristic in Garut Sheep After Estrous Synchronization Using Prostaglandin and Progesterone-CIDR *M. Agus Setiadi, Aepul*	121
OAEA 12	The Sperm Morphological Assessment of Bull Semen at Several Artificial Insemination Centers in Indonesia *R. Iis Arifiantini, Bambang Purwantara, M. Riyadhi*	123
OAEA 13	Effect of Anti-Oxidant Additive on Goat Semen Quality After Cryopreservation *S. W. Naing, H. Wahid, K. Mohd Azam, Y. Rosnina, A. B. Zuki*	125

OAEA 14 Reproductive Potency and Effort to Increase Spotted Buffalo Population in Tana Toraja 127
Yulnawati, Herdis, Hera Maheswari, M. Rizal, Arief Boediono

OAEA 15 Repair of Spiral Fracture of the Left Femur in an Ettawa Goat Using Combination Medullary, Transsegmental Pinning and Wiring 129
Dhirgo Adji

OAEA 16 The Value Of Quality Problem Orientated Veterinary Records In Teaching Veterinary Hospitals – A Case Of Cervical Spondylopathy In A Doberman Dog 131
Rashid Ibrahim

OAEA 17 Oligodendroglioma of the Interthalamic: Pathomorphology in a French Mastiff Dog 134
E. Handharyani, Hernomoadi Huminto, Adi Winarto, K. Ochiai

POSTER PRESENTATION **Page**

P 1 Identification of Bacterias That was Isolated from Origin Goat's Milk in Turi, Sleman, Yogyakarta 139
Agnesia Endang Tri Hastuti Wahyuni, Tri Untari, Franky, Satria Pinanditiya

P 2 3 in One Anti Diarrhea and Avian Influenza Egg: Production and Efficacy 141
Agustin Indrawati

P 3 The Potency of Ketamine as an Alternative Anaestheticum in Transportation of Catfish 143
Andriyanto , A. Sutisna, R. Hidayat, K. Suanda, S. Valinata, L. Andini, W. Manalu

P 4 The Effect of Ethanolic Extract of Zedoary Rhizome (*Curcuma zedoaria (Berg.*) Roscoe) Administration on Leucocytes Profile of Rabbits Which was Induced by Tumour and Treated by Combination with Surgery 145
Anita Esfandiari, Gunanti, Ietje Wintarsih, Ros Sumarny, Ridlayanti Maulida

P 5 Sensitivity Analysis of Non Radioactive-labeled Jembrana disease Virus DNA Probe Through Chromogenic Reaction 147
Asmarani Kusumawati, Penny Humaidah Hamid

P 6 Antihyperglycaemic Effect of Azadirachta indica J Extract on Alloxsan – Induced Diabetic Rat 149
Bayu Febram Prasetyo, Bambang Pontjo Priosoeryanto, Ietje Wintarsih, Rini Madyastuti

P 7 Risk Factors Related to Cutaneous Anthrax Disease Occurrence in Inhabitant of Bogor District 151
C. Basri, NM Kiptiyah

P 8 The Effects of pH on Quality of The Extract of Abomasal Mucosae (Rennet) of Local Sheep 153
C. Choliq, C. Nisa', T. Purnawarman, I. Djuwita, F. A. Sari, M. D Putra

P 9 Case Report: Echocardiography Features of Dilated Cardiomyopathy vs Hypertrophy Cardiomyopathy in Two Dogs 155
Deni Noviana, Rr. Soesatyoratih, Siti Zaenab

P 10 Experimental Study of Ionization Radiation from Radiodiagnostic Tool Radiography on Peripheral Blood of Mice (*Mus musculus*): The Preliminary research of Radioprotective Potential of Roselle (*Hibiscus sabdariffa L.*) against Radiodiagnostic Ionizing Radiation 157
Deni Noviana, Sri Estuningsih, M. F. Ulum, A. Kurniawan, B. T. Setiawan, E. M. Ningsih, G. S. Shatilla, W. Destri

P 11 Detection of Canine Distemper Virus (CDV) Using Reverse Transcriptase Polymerase Chain Reaction (RT-PCR) 159
Diah Iskandriati, Andrea Sajuthi, Endang Yuliastuti, Willy Praira, Cucu K. Sajuthi, Joko Pamungkas, Dondin Sajuthi

P 12 Detection of Hotspots Area in Malaria Surveillance in Bangka District, Indonesia 161
Etih Sudarnika, Mirnawati Sudarwanto, Asep Saefuddin, Umi cahyaningsih, Upik Kesumawati Hadi, Rita Kusriastuti, Jodi Vanden Eng, William A. Hawley

P 13 Biosecurity Measures on Broiler Farms in Subang, West Java, Indonesia 163
Etih Sudarnika, Y. Ridwan, AZ Ilyas, C Basri, DW Lukman, T. Sunartatie, BA. Wibowo, A. Sugama, P. Hermans, AJ. Nell

P 14 Production and Isolation of Ig-Y Anti-Fasciola gigantica Excretory Secretory Antigen from Yolk Eggs 165
Fadjar Satrija, Sri Murtini, Yusuf Ridwan, Elok B. Retnani

P 15 A Macroscopic Studies on Inhibitory Effect of Ethanol Extract of *Curcuma Zedoaria* (Berg.) Roscoe. Rhizomes on Tumorigenesis of Mammary Gland Which Induced by N-metil-N-nitrosourea in Rabbit 167
Gunanti, Bambang Pontjo Priosoeryanto, Ietje Wintarsih, Ros Sumarny, Janto Dwi Haryadi

P 16 The Effect of Rhizome Ethanol Extract (*Curcuma zadoria* (Berg.) *Roscoe*) Toward Clinical signs of Pre and Post Surgery in Tumor Induced Rabbit 169
Gunanti, Rini Madyastuti Purwono, Heryudianto Vibowo, Bambang Pontjo Priosoeryanto, Ros Sumarny

P 17 The Presence of Nuclear Materials During Meiotic Maturation of Recipient Oocytes Affect Developmental Ability of Somatic Cell Nuclear Transfer Embryos in Pigs 172
M. Fahrudin, K. Kikuchi, NWK Karja, M. Ozawa, T. Somfai, M. Nakai, J. Noguchi, K. Ohnuma, H. Kaneko and T. Nagai

P 18	Sequence Gastrography Technique in Campbell's Dwarf Hamster (*Phodopus campbelli*) *Mokhmad Fakhrul Ulum, Deni Noviana, Janto Dwi Haryadi, Ridlyanti Maulida, Sabrina Trisnanda Dachlan, Heryudianto Vibowo*	174
P 19	Case Study: Surgical Approach to Remove Subcutaneous Mass Tumors in a Campbell's Dwarf Hamster (*Phodopus campbelli*) *Mokhmad Fakhrul Ulum, Sri Nofriyanti Handayani, Yulia Riza, Ranti Asryyuni, Ekowati Handharyani*	177
P 20	Drinking Healthy Wild Civet Coffee (Kopi Luwak) *M. Winugroho, R. Hidayat, Atik Marijati*	180
P 21	Blood Flow Characteristics on Atria-Ventricular Valve as Assessed by Pulsed Wave Doppler Echocardiography in Normal Mongrel Indonesian Dog *Marina Wijayanti, Deni Noviana*	181
P 22	Antimicrobial Screening of Four Indonesian Medicinal Plant Activity Against Mycoplasma gallisepticum *Min Rahminiwati, Aulia Andi Mustika, Soeripto, Andriyanto, Siti Sadiah, Unang Patriana*	183
P 23	The Effect of Sipatah-patah (*Cissus quandrangularis Salisb*) Extract Administration on Quality of Bone Growth in Normal Growing Female Rats *Sabri M, Nurhidayat, K. Sigit, W. Manalu, B. P. Priosoeryanto*	185
P 24	Brucellosis on Cattle that will be Transported at Merak Port Banten from Java to Sumatra *Rahmat Hidayat, Arum Kusnila Dewi, Eko Sugeng Pribadi, Fachriyan Hasmi Pasaribu*	187
P 25	Clinical evaluation of Hydroxyapatite-Chitosan (HA-C) and Hydroxyapatite-Tricalcium Phosphate (HA-TCP) Bone Graft in Sheep's Bone as Animal Model for Human *Harry Soehartono, Gendis Aurum Paradisa, Riki Siswandi, M. Fakhrul Ulum, Gunanti*	189
P 26	Physical and Hematological Parameter of Musang Luwak (*Paradoxurus hermaphroditus*) *Sarmin*	191
P 27	Preview of Blood Glucose, Cortisol, and Physical Parameters in Bligon Goats Experiencing Transportation *Sarmin, Pudji Astuti, C. Mona Airin, Amelia Hana, Asmarani Kusumawati, Irkham Widiyono, Hera Maheswari, Luthfiralda Sjahfirdi, Mitra S, Bashori, Ariani Hasan*	193

P 28 Distribution of Glycoconjugates in the Testis of the Cave Swiflets (*Collocalia linchi*) 195
Savitri Novelina, Aryani S Satyaningtyas, Srihadi Agungpriyono, Heru Setijanto, Koeswinarning Sigit

P 29 Testicular Biopsy Gun Needle as an Alternative Biopsy Method for the Assessment of Spermatogenesis in the Kijang Muntjak (*Muntiacus muntjak muntjak*) 197
Sri Wahyuni, Srihadi Agungpriyono, I Ketut Mudite Adnyane, Muhammad Agil, Tuty Laswardi Yusuf

P 30 Immunohistochemical Study on the Development of Fetal Growth Hormone and Prolactin Cells of Long-Tailed Macaque (*Macaca fascicularis*) 199
Supratikno, Nurhidayat, N. Kusumorini, C. Nisa', S. Novelina, S. Wahyuni

P 31 Reduction of Bacterial Contamination in Chicken Farm Drinking Water by Application of Aquaoasis® Water Filtration System 201
Titiek Sunartatie, Sri Murtini, Usamah Afiff, Retno D. Soejodono

P 32 The Presence of Mosquitoes and Its Relation to Cases of Death on Dairy Cows in Pangalengan District of Bandung Regency 203
Upik Kesumawati Hadi, Susi Soviana, Supriyono

P 33 Study on Capability of Aquaoasis to Eliminate Salmonella enteritidis in Various Water Sources 205
Usamah Afiff, Titiek Sunartatie, Sri Murtini

P 34 Wound Healing Activity of Aquos Extract Aloe Vera (*Aloe barbadensis Mill*) on Gel Formulation 207
Vetnizah J, Bayu Febram Prasetyo, Ietje Wientarsih

P 35 The Impact of Disinfection and Storage in Refrigerator Against Egg's Bacterial Amount 209
Widagdo Sri Nugroho, Khrisdiana Putri, Avinda Aji Wahyu Widiarso

P 36 Identification and Characterization of Protein Dominant Epitop of Toxocara vitulorum 212
Pratiwi, Soedarto, Sarmanu, Artama

P 37 Gill Goblet Cell Proliferation of Parasites Infestated-Fresh Water Fish from Bogor Surrounding Area 214
R. Tiuria, D. Susanto, I. M. Ersa, D.F. Pazra, B. P. Priosoeryanto

P 38 Indonesian Kepel (*Stelechocarpus burahol*) as Herbal for Promoting Better Eco-Health Reducing Ammonia Emmited from Feces 216
Huda Darusman, Min Rahminiwati, Siti Saidah, Irmanida Batubara, Tohru Mitsunaga, Latifah Kosim

P 39 Preferred Anesthesia Methods for Bone Implant Surgery In Sheep As Model For Human 218
Dudung Abdullah, Raditya Pradana Putra, Riki Siswandi, Gunanti

P 40 Hematological Evaluation of Hysroxyapatite-Chitosan (HA-C) and Hydroxyapatite-Tricalcium Phosphate (HA-TCP) Bone Graft in Sheep's Bone as Animal Model for Human 220
Riki Siswandi, Dwi Kolina Pratiwi, Gunanti, M. Fakhrul Ulum, Anita Esfandiari

P 41 Radiography Evaluation of Hydroxyapatite-Chitosan (HA-C) and Hydroxyapatite-Tricalcium Phosphate (HA-TCP) Bone Graft In Sheep's Bone as Animal Model for Human 222
Riki Siswandi; Santi Purwanti; M. Fakhrul Ulum; Gunanti; Deni Noviana

P 42 Histological Evaluation of Hydroxyapatite-Tricalcium Phosphate (HA-TCP) Bone Graft In Sheep's Bone as Animal Model 224
Srihadi Agungpriyono, Asmawati Ahmad, Riki Siswandi, Kiagus Dahlan, Gunanti

P 43 Histological Evaluation of Hydroxyapatite Chitosan (HA-C) Bone Graft In Sheep's Bone as Animal Model 226
Ayu Berlianty, Srihadi Agungpriyono, Riki Siswandi, Kiagus Dahlan, Gunanti

P 44 The Effect of malathion Exposure on Rats Kidney 228
Huda Shalahudin Darusman, Razak Achmad Hamzah

P 45 Transmission Dynamics of Eimeria acervulina in a Group of Broiler Chickens 230
Ewaldus wera, Hans Vernooij, Francisca Velkers, Annemarie Bouma

P 46 Conversion of crude Protein and Crude fat of Complete Feed Rich of Omega-6 to Total Milk Protein and Milk Fat Etawa Goat 232
Emy Koestanti, Romziah S

P 47 Isolation, Characterization of Bactericin from Lactic Acid Bacteria as Microbial Effective to Dairy Cattle Mastitis Cause by Staphylococcus aureus 234
Nenny Harijani, Emy Koestanti

P 48 The Potency of Xylazine as an Alternative Anaestheticum in Transportation of Catfish 236
Andriyanto, A. Sutisna, R. Hidayat, K. Suanda, S. Valinata, L. Andini, W. Manalu

P 49 Infrastructure, management, and production performances of broiler farms in Cipunagara Subdistrict, Subang District, West Java 238
Yusuf Ridwan, E Sudarnika, DW Lukman, BA Wibowo, AZ Ilyas, C Basri, A Sugama, P Hermans, AJ Nell

P 50 Quantification Of Contacts Of Broiler Farms In Subang District With Special Reference To The Risk Of Avian Influenza Transmission 240
C. Basri, A Z. Ilyas, DW Lukman, E. Sudarnika, Y. Ridwan, Sukirman. P. Hermans, A.J. Nell

ORAL SESSION

Topic: Animal Health, Ecohealth, and Animal Production

SURFACE CHARACTER OF COAGULASE-POSITIVE AND COAGULASE-NEGATIVE OF *SATPHYLOCOCCUS AUREUS* ISOLATED FROM ORIGIN GOAT'S MILK THAT CONTRIBUTE IN ADHESION TO MAMMARY EPITHELIAL CELLS

Agnesia Endang Tri Hastuti Wahyuni [1)], M.H. Wibowo[1),] Franky[2)], B.B. Ajiguno[2),]

[1]Laboratory of Microbiology, Faculty of Veterinary Medicine, University of Gadjah Mada, Indonesia, Jl. Fauna 1, Karang Malang, Yogyakarta 55281. Telp: 62-0274-560 862, Fax: 62-0274-560 861, E-mail: wahyuni_aeth@yahoo.com
[2]Faculty of Veterinary Medicine, University of Gadjah Mada, Indonesia.

Keywords: Coagulase-positive, coagulase-negative, *Staphylococcus aureus*, adhesion,

Introduction

Once a bacterium reaches a host surface, it must be adherence to host cell to colonize them. This is particulary important areas such as the mouth, small intestine, udder and bladder where mucosal surfaces are washed by fluids. In this areas, only bacteria that can adhere to mucosal surfaces will be able to stay in the side. *Staphylococcus aureus* is an important animal and human pathogen responsible for diverse types of severe infection. In animal, *S.aureus* is a frequent cause of mastitis both in cows and goats. The mayor pathogen, *S.aureus* is generally coagulase-positive although coagulase-negative strain of *S.aureus* do occur. However,pathogenesis of the infection has not been completely define. In the pathogenesis of subclinical mastitis the adherence process is very important in the initiation step of bacteria colonization on the mammary cell surface. Surface character such as hydrophobic interaction, protein A and protein hemaglutinin are generally regarded as being an important virulence factor that responsible in the pathogenesis. This study aimed to characterize *S.aureus* coagulase positive and coagulase negative *S.aureus* that play a role in adhesion ability (associated protein A, hemagglutination ability, and the nature of hydrophobicity) to udder epithelial cells.

Materials and Methods

Research carried out using 21 cultures both coagulase-positive and coagulase-negative *S.aureus* that was isolates from of origin goat's milk. Reidentification of 21 cultures start with the colony morphology observed on blood agar plate (BAP), Gram staining, catalase test, coagulase test and mannitol fermentation tests with Mannitol Salt Agar (MSA). The production of protein A with serum soft agar test (SSA), the ability of hemagglutination with hemagglutination test using sheep blood concentration of 0.5%, 1%, 1.5%, 2%, the nature of hydrophobicity used ammonium sulfate concentration of 1.2 M; 1.6 M, 2.0 M, 2.4 M, 3.2 M. Adhesion ability of the suspension performed by labeling bacteria with fluorescein isothiocyanate (FITC) and then mixed with udder epithelial cells and observed using a microscope fluorosense.

Results and Discussion

Table 1. Adhesion of *S. aureus* isolat that were labelled with FITC to epithelial cell

No.	Code Isolate	Coagulase	SSA	HA	SAT	Mean Adhesion
1.	PH A1x	+	compac	+	+	14,3
2.	PH B2y	-	diffus	-	+	12,65
3.	PH B6y	+	diffus	+	-	8,85
4.	PH B10y	-	compac	-	+	19,4
5.	KNH A6y	-	compac	+	-	11,5
6.	KHH B5x	+	compac	+	+	12,9
7.	Irr A5x	+	diffus	-	-	14,45

+ HA : have hemagglutinin ; - HA : didn't have hemagglutinin
+ SAT : hydrophobic ; - SAT : hydrophilic

Seven of isolates *S.aureus* were adhesion test, four isolates ie A1x PH, PH B6y, KHH A5x B5x and IRR is coagulasepositive *S.aureus*. All four have a number of consecutive adhesion of 14.3, 8.85, 12.9 and 14.45 with an average adhesion figure 12.63. While the remaining three isolates B2y PH, PH B10y and KNH A6y a coagulase-negative *S.aureus* adhesion which has consecutive numbers of 12.65, 19.4 and 11.5.Average number of coagulase -negative *S.aureus* adhesion is 14.52. When compared between

the two, *S.aureus*, coagulase -positive have a lower adhesion rate. This is supported that *S.aureus* has a capable coagulase clotting process similar to the activation protrombin into thrombin and thrombin subsequently needed to change fibrinogen into fibrin. This fibrin that coats the surface of bacterial cells and protects *S. aureus* from phagocytosis activity. *S. aureus* with coagulase production tend to be resistant to phagocytosis and has a low level of adhesion.This is because the fibrin layer covering the surface *S. aureus* cover the expression of other surface proteins to bind to host cell receptors that had hampered this adhesion. Similar results found in *S.aureus* isolated from dairy cow milk Akmil Magelang, where *S. aureus* coagulase-positive have a lower level of adhesion than the *S. aureus*, coagulase -negative. However, if significance is measured using T-test with siginifikasi 0.05 level, indicating that the level of adhesion between the isolates of *S. aureus* and coagulase -positive *S.aureus*, coagulase-negative that comes from goat's milk does not differ significantly (> 0.05). This was likely influenced by several factors other than coagulase. The presence of other surface proteins such as protein A, FnBP, and also the surface hydrophobicity of bacteria is a factor that helped determine the level of bacterial adhesion to host cells.

Character of both coagulase-positive *S.aureus* and coagulase- negative, which tend to have high protein A marked most compact form colonies on the SSA media, and are hydrophobic hemaglutinated of erythrocytes have a high level of adhesion. While *S. aureus*, which tend to have low-protein A, which is marked largely formed diffuse colonies in SSA medium, slightly hemaglutinated of erythrocytes, and the hydrophilic portion has a low level of adhesion. Influence of the presence of coagulase coagulase-positive *S.aureus* showed a lower level than the adhesion of *S.aureus*, coagulase-negative, although not significantly different.

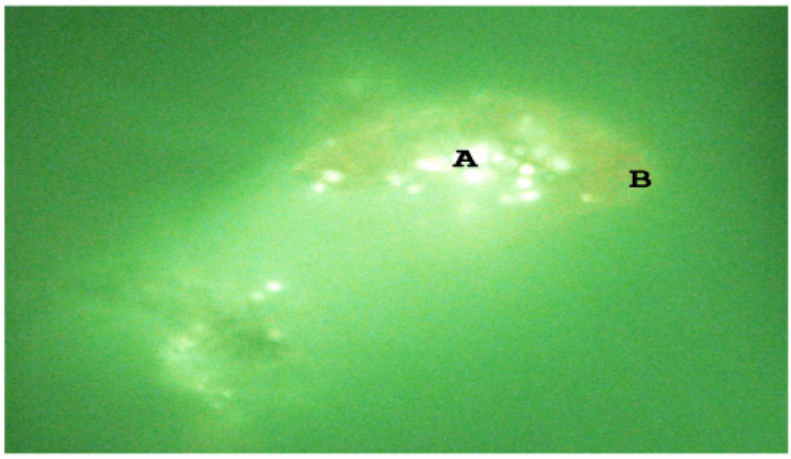

Figure 1. Adhesion of *S.aureus to* epithelial cells of udder
A : S.aureus B: ephithelial cells of udder

Conclusion

Staphylococcus aureus both coagulase-positive *S.aureus* and coagulase-negative *S.aureus*, indicating that the presence of protein A, haemagglutinine and a hydrophobic had higher adhesion in epithelial celsl. Coagulase-positive of *S.aureus* has a lower adhesion capacity than coagulase-negative *S.aureus*. The presence of protein A, the haemagglutinin, coagulase and bacterial cell surface hydrophobicity influences the level of adhesion to host cells.

References

Almeida, R.A., K.R. Matthew, F., Cifrian, A.J. Guidry, and Oliver S.P. 1996. Staphylococcus aureus invasion of bovine mammary epithelial cells. J.Dairy. Sci. 79:1021-1026.

Baselga, R., I. Albizu, M. D. L. Cruz, E. D. Cacho, M.Barberan, dan B. Amorema. 1993. Phase Variation of Slime Production in *Staphylococcus aureus*: implication in Colonization and Virulence. *Infect. Imun*. 61 (11): 4857-4862.

Carter, G.R., and D.J. Wise. 2004. Essential of Veterinary Bacteriology and Mycology. Sixt Edition. Iowa State Press. 193-197.

Ruegg, P.L., 2003. Investigation of mastitis problem on farm. Vet.Clin.N.Am Food Anim. Pract 19:47-73.

Taverna, F., Armando, N., Renata, P., Alfonzo Z., Simona, N., Severino,R., Gabriella, T. 2006. Characterization of cell wall associated proteins of *Staphylococcus aureus* isolated from bovine mastitis case by proteominc approach. Vet. Microbiol. 119:240-247.

Zhang, S., Maddox, C.W. 2000. Cytotoxic activity of coagulase-negative Staphylococci in bovine mastitis. Infect.Immun.68: 1102-1108.

DETECTION OF *STREPTOCOCCUS AGALACTIAE* INFECTED TO MOUSE MAMMARY GLAND AS A MODEL FOR BOVINE SUBCLINICAL MASTITIS.

Sri Estuningsih

*Division of veterinary Pathology**
Department of Clinic, Reproduction abd Pathology
Bogor Agricultural University
Jalan Agatis, Kampus IPB Darmaga, Bogor, 16881
West Java-Indonesia

Keywords: *S. agalactiae*, subclinical mastitis, mouse mammary gland

e-mail: estu-patoipb@yahoo.co.id

Introduction

Subclinical mastitis caused by *S. agalactiae* might have a substantial impact on quantity and quality of the milk produced. *Streptococcus agalactiae* can survive for long periods within the mammary gland with rarely causing clinical symptom and make unidentified infected cattle, which are not selected for treatment; those cattle may function as reservoirs of infection. The last knowledge of *S. agalactiae* mastitis has been reviewed by Keefe (1997). According to this author there has been a shift from the high intra herd prevalence of the 1970s and 1980s to a low intra herd prevalence today.

Experimental mastitis due to infection of bovine mastitis had been done since many years ago (Reid and Anderson, 1976; Chandler, 1973, 1975). Those experiments clearly described about pathogenesis of mastitis cause by bacteria as well describe pathological changes of mammary tissue of the mouse. The sites of that bacteria inside the cells also had done by electron microscopy (Chandler, 1978). Eventhough the colony of *S. agalactiae* are seen in most of experimental mastitis in the mouse, but the information about location of that bacteria related to the time of infection is not yet known. This experiment was performed to show the impact of *S. agalactiae* in mammary gland tissue over period of 8 days infection.

Materials and Methods

Eight ten of 10 weeks old lactating Balb-c mice were used for this study. Mice were divided into 3 groups following the time of infection (1 day, 4 days and 8 days) each 5 mice and 3 mice as negative control. Mice were kept individually and separated from offspring 1 day before bacterial inoculation.

Inoculate was bacterial suspension which contain 10^9 CFU/ml of *S. agalactiae.* Bacteria were isolated from subclinical bovine mastitis and well characterized by classical microbiological method and using PCR (Estuningsih, 2001). Bacteria were suspended in PBS and diluted to the density of 10^9CFU/ml. Using micropipette 50 µl of this bacterial suspension were used as inoculate and were dropped into lumen of mammary teats of lactating mice.

Mice were kept singly following time of infection as well as control mice. Mice terminated by atlanto-occipital dislocation and mammary glands were collected. Mammary glands were fixed in 10% of Buffered Normal Formalin. Histopathological study were done with staining of Haematoxylin-Eosin (HE) and immunohistochemistry. Pre-treatment for immunohistochemisty was protease 0,5% (Sigma).

Monoclonal antibody against *S. agalactiae* (Qued Bioscience, CA, USA) were used with dilution of 1 : 1000 to detect *S. agalactiae* in the mouse mammary tissue with ARK™ (DAKO, Denmark) as staining system.

Results and Discussion

This experiment were design to explain that bacteria which enter to the teat lumen from environment as well hands while milking were able to produce a subclinical mastitis. By dropping 50 µl of bacterial suspension in to the teat lumen, bacteria able to enter the teat canal and passed it than adhere on the alveolar mammary epithelial cells.

Bacterial inoculate were given and examine after 1 day (24 hours), 4 days and 8 days infection. The morphology of the mammary glands 1 day after infected were still relatively normal, glands were composed by alveolar glands. Milk secretion seen filling the alveolar cavity as well the duct system. Another mammary glands reaction in 1 day post infection were desquamation of alveolar mammary epithelial cells. Macrophages and Polymorphonucleated cells (Neutrophil) were seen together in the

alveolar lumen as well in the interstitium, those cells usually contain cocci which have had phagocyted and showed as brown color with immunohistochemistry.

Histopathological changes of mouse mammary glands 4 days post infection by *S. agalactiae* was dominated by inflammatory reaction. The architecture of mammary glands were almost shrunken, alveolar lumen became narrow, some of alveolar lumen still retain some milk secretion and fat globule also reduce. Bacteria were seen in the area of inflammation.

In 8 days p.i. of *S. agalactiae* cause severe fat replacing tissue compare with normal mouse mammary gland. Alveolar lumen disappear, only some of alveolar lumen which still contain milk secretion. By immunohistochemistry using monoclonal antibody against *S. agalactiae* were showed that bacteria were entrapped in fat tissue.

This research suggested that *S. agalactiae* is an obligat intramammary bacteria causing permanent subclinical mastitis which could be spread out from hand or milking machine.

Conclusion

Histopathology in this experimental subclinical mastitis in the 1 day post infection were accumulation of *S. agalactiae in* macrophage and neutrophil in the mammary alveolar lumen and mammary interstitial tissue; in 4th day post infection *S. agalactiae* shown in the inflammatory site contain macrophage, lymphocyte, fibroblast, cellular debris; in 8th day post infection *S. agalactia* were laid and entrapped among fat cells which replace necrotic mammary gland tissue.

References

Anderson, J. C. and R. L. Chandler. 1975. Experimental staphylococcal mastitis in the mouse : Histological, ultrastructural and bacteriological changes caused by a virulent strain of *Staphylococcus aureus* . *Journal of Comparative Pathology* 85(4) : 499-510 .

Chandler RL. 1973. Ultrasructural and associated studies on experimental mastitis in the mouse produced by three strains of streptococcus. *Br J Exp Pathol* 54:267-273.

Estuningsih S, I Soedarmanto , K Fink , C. Lammler and I. W. T. Wibawan. 2001. Studies on *Streptococcus agalactiae* Isolated from Bovine Mastitis in Indonesia. *J. Vet. Med* 49, 185-187

Reid, IM , R.D. Harrison and J.C. Anderson. 1976. Experimental staphylococcal mastitis in the mouse: A morphometric study of early changes in mammary gland structure . *Journal of Comparative Pathology, 329-336*

Keefe, G. P., 1997: *Streptococcus agalactiae* mastitis: a review. *Can. Vet. J.* 38 ,429-437.

STUDY PROTECTIVITY OF IMMUNOGLOBULIN Y (IG-Y) AGAINST *AEROMONAS HYDROPHILA* IN CARP FISH (*CYPRINUS CARPIO L.*)

Rahmat Hidayat[1]

[1]*Department of Animal Disease and Veterinary Public Health Science, Faculty of Veterinary Medicine, Bogor Agricultural University-16680*

Keywords *: Feed, carp fish, A. hydrophila, immunoglobulin Y*

Introduction

Fish diseases caused by bacterial attack *Aeromonas* sp. many reported and caused great losses, especially in freshwater fish species. In Indonesia, an outbreak occurred in 1980, particularly in rural West Java and the surrounding areas. Mid-2002, Department of Livestock and Fisheries of Bogor District reported total number of dead Carp fish in the attack allegedly bacteria *Aeromonas hydrophila* reached 200 tons and the Brass Local Government of Kuningan reports that mentioned the death of Carp 800 tons of fish ready to sell.

Immunoglobulin Y (Ig-Y) is an immunoglobulin with the lowest molecular weight on the body of poultry, reptiles and amphibians. Ig-Y has a biological trait that is a combination of nature bilogik Ig-G and Ig-E (Wibawan *et al.* 2003)

Materials and Methods

Samples of whole fish obtained from traditional markets in the city of Bogor. Selected bacterial isolates were grown in liquid culture media BHI 100 ml, then let stand for 18 hours. After that the bacteria were centrifused at 5000 rpm for 15 minutes, so that forming a separation supernatan and sediment. Supernatan discarded, while the bacterial sediment washed or dissolved in 10 ml PBS. Washing 1 (one) times again, then centrifused until sediment is formed and then dissolved in 10 ml of PBS, the outcome is a bacterial suspension with concentration 10^9 cfu / ml (Wibawan *et al.* 2003).

Then the bacterial suspension was heated in a *water bath* at a temperature of 60 ^{0}C for 1 hour, check with a sterility test TSA for 18-24 hours. If you have proven sterile, then do the injection on the egg-laying chickens are ready intravenously for 4 (four) weeks.

In the first week carried out a one-time injection of chicken with a dose of 0.1 ml. Later in the second week, third and fourth done three times for days successively in each week with a dose of each injection 1 ml. Chickens that had been injected on a regular basis, a week later is expected to lay eggs and will produce eggs containing anti-Ig-Y - *A. hydrophila.*

Serum test performed every week starting the first week after vaccination done. Chicken serum was taken through the *axillary vein* and measured during 12 (twelve) weeks. While testing Ig-Y from egg yolk is done daily, after previously performed the separation of yolk from the whites of eggs on filter paper. The testing is done by the method *Agar Gel Presipitation Test* (AGPT).

Commercial fish pellets made dough by mixing warm water and sago flour, then egg yolks containing Ig-Y mixed dough evenly into the fish feed (pellet). Dough ground using a meat cutter, cut into pieces the size of initial and dried pellets.

The new pellet mixture is given as fish feed for 14 and 30 days with different dose for 2 (two) groups of fish treatment, the low dose group and high dose groups. While fish are not mixed with egg yolk applied to 1 (one) the control group. After getting the bacteria *A. hydrophila* is a pathogen, and bacteria are injected to the treatment and control fish. Then on the final stage of research carried out counting the percentage of morbidity from lesio formed and mortality of each fish group.

Results and Discussion

Positive isolates *A. hydrophila* from each Traditional Markets and Supermarkets is 2 and 1.

Identification of Ig Y in the egg yolks with the test conducted AGPT. Positive results shown by the formation of precipitation lines between Ig Y in the supernatant with bacterial *A. hydophila.* Positive for egg yolk Ig Y since the third week after the last vaccination rather dated October 11, 2005 and ending negative November 29, 2005.

Table 1. Results Identification of Immunoglobulin Y

Week	Serum	Yellow Eggs
01	+	-
02	+	-
03	+	+
04	+	+
05	+	+
06	+	+
07	+	+
08	+	+
09	+	+
10	+	+
11	+	+
12	+	-

Ig-Y, which are harvested from egg yolk could reach half a liter of chicken eggs produced during a month. This amount is ten times more when compared to the amount produced in the blood (Nakai *et al.* 1994).

Table 2. Percentage of Morbidity and Mortality in Carp Fish

Group	Giving 14 days		Giving 30 days	
	Morbidity	Mortality	Morbidity	Mortality
Low Dose	42.86%	0%	0%	0%
High Dose	0%	0%	0%	0%
Control	100%	100%	100%	75%

The results obtained in Carp fish showed that administration of Ig-Y provides significant immunity compared to control. Low dose 14-day provision could suppress the death of up to 0% but not effective enough to prevent pain (42.86%). While the 30-day delivery for both low and high doses of high gives a better result because it can suppress morbidity and mortality to 0%.

A. hydrophila including microbes that are opportunists who do not only cause disease in fish, but also for humans. In humans, this bacterial pathogens in the intestine, causing *gastroenteritis* disease, especially persistent diarrhea and dysentery (Taher *et al.* 2000).

Conclusions

Based on test results can be concluded that the addition of Ig-Y in pellet may provide protection to Carp fish against infection *A. hydrophila.* Need to do a more in-depth research on the use of Ig-Y titer and long the most effective delivery.

References

Nakai S, Li-chan E, Lo KV. 1994. Separation of Immunoglobulin From Egg Yolk. In Egg Uses and Processing Technologies. Edited by J.S. Sim and S. Nakai. CAB Intl pp 94 – 105.

Taher, A. A. I., *et. al.,* 2000. An outbreak of acute gastroenteritis due to *Aeromonas sobria* in Benghazi, Libyan Arab Jamahiriya. Vol. 6, Issue 2/3, pp. 497-499.

Wibawan, IWT, Retno DS, Chandramaya SD, Tiok BT 2003. Immunological diktat. Faculty of Veterinary Medicine. Bogor Agricultural University.

BLOOD PROFILE OF RATS (*RATTUS NORVEGICUS*) CONTRACT LUNG CANCER TREATED WITH GOAT'S MILK PEPTIDE

Anwar M[1], Retno SW [1], Romziah S[2]

[1]Department of Basic Veterinary Medicine, Faculty of Veterinary Medicine Airlangga University,Surabaya Indonesia, email : anmalian@unair.ac.id
[2]Department of Animal Production, Faculty of Veterinary Medicine Airlangga University, Kampus C UNAIR Jl. Mulyorejo, Surabaya Indonesia

Keywords: Blood profile, benzapirine, goat's milk peptide

Introduction

Goat's milk contains bioactive peptide similar to human milk bioactive. Casein and whey protein are the main protein source in milk that contain bioactive milk peptides. These bioactive peptides are able to enhance both human's and animal's health, particularly in immune response mechanism. Bioactive milk peptide in the form of gamma interferon, lactoferin and lysosome function as antibacteria and are able to repair damaged cells.

This study aims to identify the potential of goat milk peptide as efficacious antibacterial and anti cancer milk in rat model (rattus norvegicus) induced lung cancer through rats' blood profiles including total erythrocyte, Haemoglobin, PCV and total leukocyte.

Materials and Methods

Experimental animals used in this study were twenty male 10-12 weeks old Wistar rats. Rats were injected four times with 200 mg/kg bw of benzapirene (BZP) daily. Treatment groups in this study were F0 : control group (without benzapirene injection); F1 : benzapirene injected group, without goat's milk protein peptide treatment; F2 : benzapirene injected group, treated with goat's milk protein peptide (Enzyme); F3 : benzapirene injected group, treated with goat's milk protein peptide (Probiotic). The administration of 20 mg/kg bw of goat's milk protein peptide was administered daily for one week. Seven days later, blood sample was collected for examination.

Results and Discussion

Table 1. showed the blood profiles of each treatment group. Total erythrocyte in group F0, F1, F2 and F3 were respectively 8.758, 7.793, 7.920 and 7.096 millions/mm3. Statistically there was no significant difference among treatment groups. Haemoglobin levels were 14.51, 13.10, 14.79 and 13.58 g % where there were no significant difference between F1 and F2 also, there was no significant difference between F2 and F3. In this study PCV was found still in normal range in all treatment groups i.e. 44.66, 39.24, 39.20 and 38.40 %, meanwhile statistically there was a significant difference between group F2 and F3, and no significant difference among group F0, F1 and F2 ($p>0.05$).Total leukocyte in treatment groups were respectively 10.33, 8.17, 7.86 and 7.51 which were significantly different between F1 and F2 but not between F2 and F3 ($p>0.05$).

Blood formation process depends on the availability of oxygen. In experimental rats that contract cancer there is impairment in oxygen absorption. This can be seen in group F1 that consisted of rats with cancer without goat's milk peptide treatment. In this group, a reduction of total erythrocyte, haemoglobin as well as PCV were found. Apart from oxygen, the availability of protein also really affect erythropoiesis, In treatment group F2 and F3 which received goat's milk peptide there was an increase of the number of blood erythrocyte, haemoglobin and PCV. The administration of feed contained both probiotic and enzyme gave the same effect in increasing feed digestion coefficient therefore the goat's milk yielded posses high protein as well ass the milk peptide content precursors. This is in accordance with the oppinion of Brink (2000) stated that bioactive goat's milk peptide is able to fix damaged cells and to reduce the number of total leukocyte so that it can be said that the administration of bioactive goat's milk was able to suppress inflamation.

Table 1. The Means (± Standart Deviations) of Rats Blood Profile in Various Treatments

Parameters	F0	F1	F2	F3
Total erythrocyte	8.75 ± 0.58	7.79 ± 1.00	7.92 ± 0.87	8.09 ± 0.98
Haemoglobin	14.51 ± 1.10	13.10 ± 1.07	14.79 ± 0.34	14.83 ± 0.81
PCV	44.66 ± 3.80	39.24 ± 3.16	39.20 ± 2.48	39.42 ± 4.03
Total leukocyte	10.33 ± 1.69	8.17 ± 1.11	7.86 ± 0.92	7.51 ± 1.18

Conclusion

Results show that blood levels of total erythrocyte, Hb and PCV of rats from group F2 and F3 were higher compared to those of F0 and F1. These facts led to a conclusion that the administration of goat's milk peptide could increase blood levels of total erythrocyte, Hb and PCV. Meanwhile in this group total blood leucocyte level declined. It showed that the administration of goat's milk peptides could suppress infection in lung cancer on rats.

References

Aluko,RE. 2007. Technology for Production and Utilization of Blood Protein-Derived Antihypertensive peptide : a review. Recent Patents in Biotechnology 1., 260 -267.

Brink, W. 2000. The Bioactive Peptide That Fight Diseases. E. Magazine, October. http://www.lef.org.

Romziah,S,Anwar,M dan Retno Sri W. 2008. Induksi Agen Conjugated Linoleic Acid Dalam Pembuatan Pakan Komplit Berkhasiat Anti –Carsinogenic. II. MENRISTEK.

STUDY ON VIRAL INACTIVATION CAPABILITY OF AQUAOASIS AGAINST H5N1 AVIAN INFLUENZA VIRUS

Sri Murtini, Retno D. Soejodono, Usamah Afiff, Titiek Sunartatie

Division of Medical Microbiology, Department of Animal Diseases and Veterinary Public Health, Faculty of Veterinary Medicine, Bogor Agricultural University, Jl. Agatis Kampus IPB Darmaga-Bogor, Indonesia

Introduction

Various pathogen microorganisms including avian influenza virus H5N1 or bird flu virus may contaminate and spread through surface water. Water treatment using filtration device become a reliable technique in prevention of pathogens contamination in the water. Implementation of the device may reduce possible water contamination and thereby enhance the water quality.

Aquaoasis is a water filtration device which designed to inactivate contaminant microorganisms by filtration and ozonisation. Molecular ozone or its decomposition products (for example, hydroxyl radical) inactivate micro organisms rapidly by reacting with intracellular enzymes, nucleic material and components of their cell envelope, spore coats, or viral capsids.

The present study was carried out to test capability of Aquaoasis ® water filtration system to inactivate/eliminate virus (avian influenza H5N1) in water under laboratory condition.

Materials and Methods

The test was carried out in four 200 L-water tanks which were installed with Aquaoasis (treatment tanks C and D), or with conventional water pump (control tanks A and B). Prior to the test, pre-treated water samples were taken in three depth spots (surface, middle, bottom). Avian Influenza H5N1 virus suspension of 10^{11}EID $_{50}$ (tank A and C) and 10^{9}EID $_{50}$ (tank B and D) were added to the tank, making the final average concentration of virus in the water is 0,5 x10^{6}EID $_{50}$/ml and 0,5 x10^{4}EID $_{50}$/ml. The aquaoasis and the conventional water pump were subsequently turned on. For the first hour of water treatment, water samples tank A and C were taken every 30 minutes. Later, until the next 6 hours, the samples were taken every hour. Then, until the end of the experiment (96 hours), samples were taken every 24 hours. For tank B and D, samples were taken every 30 minutes until the end of the experiment on hour 3. Presence of the virus contamination was checked by taking water samples. Each water sample was inoculated in three specific AI antibody free embrionated chicken eggs. Presences of H5N1 virus in the allantoic fluid from the embrionated chicken eggs were identified using rapid agglutination test and PCR using primer J3 and B2a (Slomka 2007)

Results and Discussion

Analyses of water samples taken before and after 4-hour treatment with AO before adding the virus did not find any AI virus contamination (Tables 1) it's indicates that the AI test viruses were the only source of virus in the test tanks. Results of the test are presented in Figure 1.Avian influenza H5N1 virus at concentration level of 0,5x 10^{6}EID $_{50}$/ml survived in 200 L of water circulated using a conventional water pump (control) for at least four days. Utilization of aquaoasis to treat the viral contaminated water was able to clean the virus after 48 hours continous treatment. Water with lower virus concentration can be cleaned within 1 hour. No more AI virus was able to be recovered from eggs inoculated with water samples after being continously treated with AO for 48 and 96 hours. The RT-PCR test showed that virus in the water tank which treated by AO as disappear at 48 hours after treatment, whereas the virus can still be isolated from water samples in the untreated water tank until 48 hours after treatment (Figures 2).

Table 1. Virus recovery from water samples before added virus

Sampling period	Sampling location in the tanks	Recovery of AIV in eggs (%)
Before AO and water pump operation	Surface	0
	Middle	0
	Bottom	0
4 hour after AO and water pump operation	Surface	0
	Middle	0
	Bottom	0

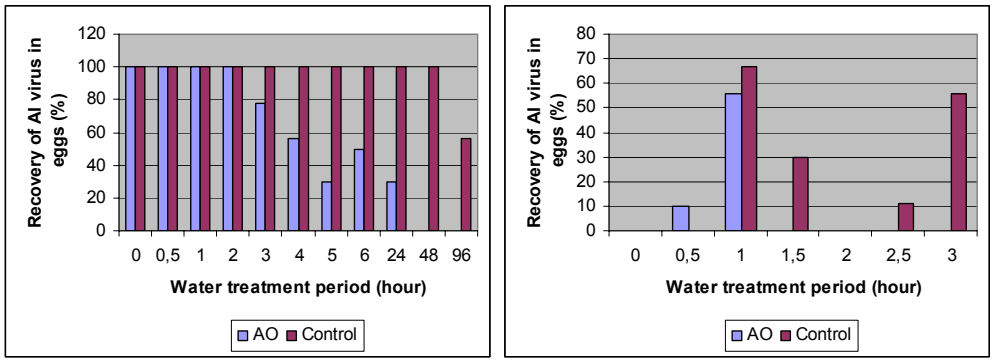

A B

Figure 1. Percentage of virus recovery from embryonated chicken eggs inoculated with water samples taken from AO treated and control tanks during the experiment (A : tank A and C) (B: tank B and D).

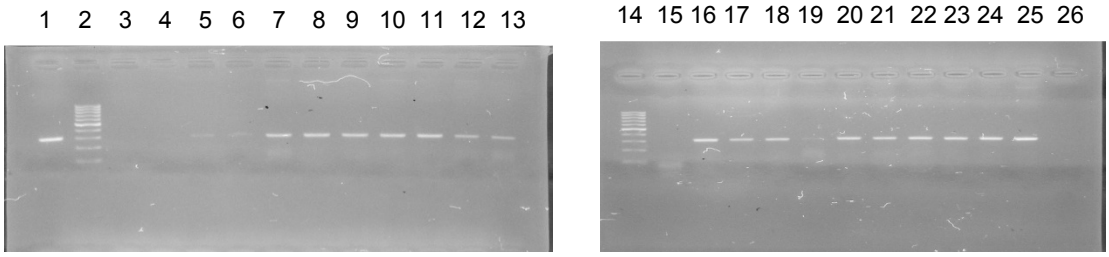

A B

Figure 2. PCR result from AO treated water (A) and untreated water (B)
well (1) positive control, (2) Marker (3) negative control (4) AF of water samples at 48 hours (5-12) AF of water samples at 24hours-30 minute (13) AF of water before AO treatment.
AF= allantoic fluid

A much faster virus clearance was achieved when AO was used to clean virus in previously treated water. The results suggest that length of the period required to clear virus contamination is influenced by the virus concentration in the water and the quality of water. Based on Hoigné and Bader (1985) study Purity and pH of water greatly affect the rate of ozone solubilisation. Very low ozone residuals (<0.01mg/l) at 5 °C and pH 7 able to inactivated Feline Calici Virus and Adenovirus (Thurston-Enriquez et al. 2005).Aquaoasis produced ozone that capable to destroy viral protein. The surface proteins such as haemaglutinin (HA) and Neuroamidase (N) which contained in envelope and capsid of H5N1 AI virus, will be destroyed by the ozone which Aquaoasis produced. The destruction of these surface protein will led to the destruction of the virus itself as the ozone molecule acts as dipole with electrophilic and nucleophilic properties. Aqueous ozone inactivated f2 and T4 bacteriophages by attacking capsid protein, with liberation and inactivation of the nucleic acid (Sproul and Kim 1980).

Conclusions

- Aquaoasis tested under laboratory condition showed capability to clean H5N1 AI virus contamination in the water.
- Elimination of the virus in the water required continous AO treatment for 1-8 hours depending on the level of virus contamination.

References

Hoigné J, Bader H. 1985. Rate constants of reactions of ozone with organic and inorganic compounds in water. III:Inorganic compounds and radicals. Water Res 19:993.

Sproul OJ, Kim CK. 1980. The mechanism of ozone inactivation of waterborne viruses. Report (1980) (W81-00315, OWRT-B-013-ME/2), Order No. PB81- 27334). From Government Rep Announce-Index (U.S.)1981. 81(5),861.

Staehelin J, Hoigné J. 1985. Decomposition of ozone in water in the presence of organic solutes acting as promoters and inhibitors of radical chain reactions. Environ Sci Technol 19:1206-1213.

Slomka MJ, Cowrad VJ, Banks J, Löndt BZ, Brown IH, Voermans J, Koch G, Handberg KJ, Jørgensen PH, Cherbonnel-Pansart M, Jestin V, Cattoli G, Capua I, Ejedersund A, Thorén P, Czifra G. 2007. Identification of sensitive and spesific avian influenza polymerase chain reaction methods through blind ring trials organized in the European Union. Avian Dis. 51: 227-234.

Thurston-Enriquez JA, Haas C.N, Jacangelo J, and Gerba C.P.2005. Inactivation of enteric adenovirus and feline calicivirus by ozone Water Research 39: 3650-3656.

ANTI AVIAN INFLUENZA NUTRITIONAL FOOD AS SOLUTION FOR MEDICATION OF AVIAN INFLUENZA DISEASES IN HUMAN

Retno D. Soejodono, Sri Murtini, Wayan T. Wibawan

Keyword: IgY, avian influenza, passive immunization

Introduction

Passive immunization by oral administration of specific antibodies is an attractive approach to prevent and cure of bacterial or viral infection establish in humans and animals. Oral administration of IgY has proven to be successful for the treatment of a variety of gastrointestinal (GI) pathogens such as bovine and human rotaviruses, bovine coronavirus, *Yersinia ruckeri*, enterotoxigenic *Escherichia coli, Salmonella* spp., *Edwardsiella*, *Staphylococcus*, and *Pseudomonas* (Nolan and Mine 2005). Avian influenza diseases is one of the fatal human infection, neither vaccine nor medicine has not developed yet for those diseases. Passive immunization by Oral administration of IgY is an emerging and promising nutritional strategy that may serve to control avian influenza infection in human.This research was aimed to to study of egg yolk immunoglobulin (IgY) anti avian influenza as nutritional food for medication of avian influenza diseases in human.

Methods

Ten of 20 week old Isa Brown hens which vaccinated by H5N1 AI virus vaccine.twice with four week. One week after second vaccination the egg were collected to analyses the present of IgY anti AI H5N1 in the egg yolk. the present of IgY anti AI H5N1 were determinet by haemagglutination inhibition (HI) test (OIE 2005). The egg yolk containt IgY anti AI H5N1 were spray dryng become egg flour. The egg flour containt IgY anti AI H5N1 were exposed to low and hig pH (4 and 9) and digestive enzym (pepsin and tripsin) and than analysed the IgY anti AI H5N1 by HI test. Virus neutralization test agains AI H5N1 field isolates were performed to find out the effication of IgY in egg flour form. To test the prospek of IgY for passive immunization by oral administration, the egg flour was made to rat feed .. 20% egg flour pelets were given to the rat and the present of IgY in the plasma were tested before and two hours after feeding.by ELISA.

Results and Discussion

Specific IgY development and production can be achieved by immunizing layinghens with the target antigen. By vaccinatedhen with H5N1 vaccine twice the hen was able to produced egg contain IgY anti AI with titer 2^7. After spray drying the IgY titer were still high (2^7) in the egg flour. According to Yokoyama et al. (1992) study IgY powders obtained by spray-drying or freeze-drying the water-soluble fraction of egg yolks did not show a significant alteration in antibody titres.

Biological test show that the IgY titer remain high after being expose to low and high pH . IgY were stabil in the acid and alkali condition, Shimizu et al.(1993) studied that the activity of IgY was decreased at pH 3.5 or lower and almost completely lost with irreversible change at pH 3, under alkaline conditions, the activity of IgY did not change until the pH increased to 11. IgY titer decrease from 2^7 to 2^1 after exposed to pepsin and trypsin enzymes. The stability of IgY against pepsin appears to be highly dependent on pH and the enzyme/substrate ratio. At pH 5 or higher, IgY was fairly resistant to pepsin but at pH 4.5 or below, IgY complete hydrolysis of the antibody molecule, leaving only small peptides (Shimizu et al., 1988).

Efication test of IgY agains H5N1 AI virus field isolates showed that IgY with titer 2^5 and 2^4can be neutralized virus AI 100% . This resuls indicating that egg flour containt IgY anti AI virus were potential to made nutricical food without lossing the efication. The pellet for rat were made from egg flour was given to rat. IgY can be detected in the plasma of rats fed with cookies containing 20% egg flour 30-60 minute after feeding at concentration level of 0,0047-0,0048µg/ml plasma. It showed that IgY remain resisten of heat and digestive enzym during digestive proses in the rat.

Conclusion

Result of the experiment suggest that IgY anti AI H5N1 in the egg flour is potential roles to be nutritional food for medication of avian influenza diseases in human

References

Nolan KC.J. and Mine, Y. (2005) Passive immunization through avian egg antibodies. *Food Biotechnology* 18: 39-62.

Shimizu M., Nakai S. & Fitzsimmons R.C., 1988. An-*E. Coli* immunoglobulin Y isolated from egg yolk of immunized chickens as a potential food ingredient. *J. Food Sci*., 5, 1360-1366.

Shimizu M., Nagashima H., Sano K. & Hashimoto K., 1993. Comparative studies on molecular stability of immunoglobulin G from different species. *Comp. Biochem. Physiol*., 106(2), 255-261.

Yokoyama H. et al., 1998b. Oral passive immunization against experimental Salmonellosis in mice using chicken egg yolk antibodies specific for *Salmonella* Enteritidis and *S*. Typhimurium. *Vaccine*, 16(4), 388-393.

IDENTIFICATION OF GASTROINTESTINAL WORMS FROM EGG FECAL SAMPLES OF BAWEAN DEER (*Axis kuhlii*) IN SURABAYA ZOOLOGICAL GARDEN

Setiawan Koesdarto[1],Ahmad Hunaifi[2],Hario Puntodewo Siswanto[3], Endang Suprihati[1]

[1]Department of Parasitology, [2]Student of PPDH, [3]Department of Veterinary Public Health, Faculty of Veterinary Medicine, Airlangga University,Campus C,Mulyorejo-Surabaya60115

Keywords: Gastrointestinal worms egg, Bawean deer, Surabaya zoological garden

Introduction

The Sambar deer (*Axis kuhlii*), one of the rare wild animal in the world, which there population restricted at the Bawean island (190 km^2) (Semiadi, 2004).

The changes of habitat, suffer from a loss habitat, the illegal hunter and excessive exploitation cause of decration of the population.

The effort from the zoo garden were optimalization for control of the animal health.Disease caused by a worm parasite generally do not cause the death, but taking place chronicaly, so the animals will loss the production, while at the young animal, emaciasi, the growth will decrease, anaemia and diarrhoea (Koesdarto,2009). The purpose of this research was to assist for obtain information which could use for controlling the helminthiasis at bawean deer.

Materials and Methods

The survey were done, with taking stool samples of based on totally 50 of bawean deer (25 from cage and 25 from free ranging.The samples didn't differentiate among sexes, body weight and ages.

Stool collected from bawean deer (*Axis kuhlii*), with formaline 10% as a preservative, through the identification using microscopically, based on size and characteristic morphology of eggs worm, we used some methods (native, simple sedimentation and floating), to analyze the data we use the chi square test.

Results and Discussion

The examination of 50 stool samples bawean deer, from different location (cage and free ranging) at the zoo, were point out that 29 samples (58 %) were positive, and 21 samples (42 %) negative.

From the qualitative examination, we could identify five genus of the gastrointestinal egg worm, there were:*Haemonchus* sp, *Trichostrongylus* sp*, Trichuris* sp*, Toxocara* sp dan *Fasciola* sp.

Table 1 The percentage of egg worm infection at the bawean deer, Surabaya zoo

Location	Positive egg	%	Negative egg	%	Total
Cage	16	64	9	36	25
Free ranging	13	52	12	48	25
Total	29	58	21	42	50

According of the Table 1, the percentage of the gastrointestinal egg worm, from the bawean deer, at the cage were 64 % (16 samples) and the bawean deer from the free ranging were 52 % (13 samples).The egg worm infection of the bawean deer from the cage and free ranging, it cause by five genus of worm infection, it consist of Trichuris sp.(37.9%), Trichostrongylus sp.(20,7 %), Fasciola sp.(17,2 %),Toxocara sp.(13,8 %), and Haemonchus sp.(10,3 %). The summary of the total of egg worm at bawean deer, during this study were serve at Fig.1.

The fecal samples from the bawean deer in the cage were 16 samples positive (64%),meanwhile in the free ranging were 13 samples positive (52%). Helminths occurence because of contamination grass by worms egg or infective larvae, where in this case grass were perform in the feeding animal, which taking from padi field surrounding Surabaya (Koesdarto,2009). According to Boever (1986), Varadharajan and Pythal (1999) helminths from most class Nematoda is often met in deer digestive system, were Trichuris spp. and Oesophagustomum spp., Strongyloides spp., Fasciola spp. and Toxocara spp. The helminths egg and number of percentages were identified of the Sambar deer at Surabaya Zoo, were, Trichostrongylus spp. (45,45%), Fasciola spp. (15,91%), Haemonchus spp. (13,64%), Paramphistomum spp. (11,36%), Strongyloides spp. (6,82%), and Toxocara spp. (6,82%) (Koesdarto, et al., 2009).

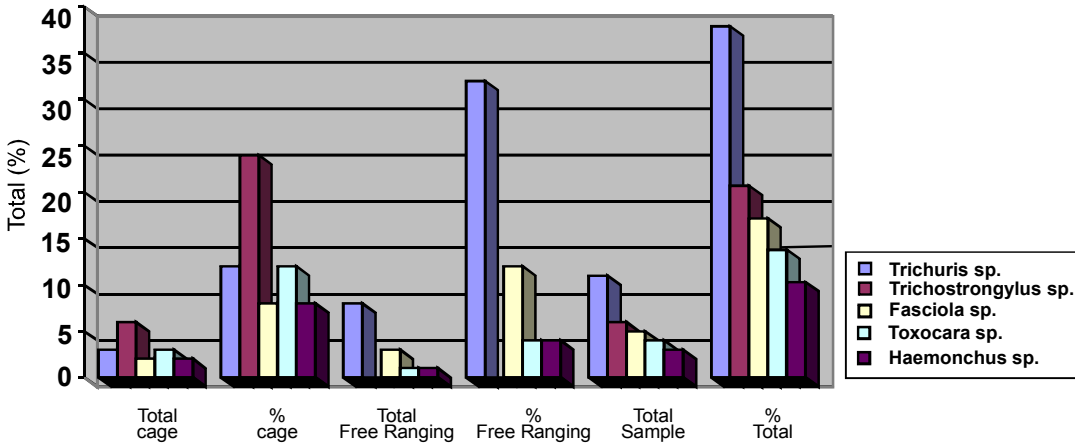

Fig.1. Graphic of total and type of egg worms at Bawean deer

Conclusion

The identification of worms egg, which infect its from: nematodes, consist of Haemonchus spp., Trichostrongylus spp., Trichuris spp and Toxocara spp; trematodes, consist of Fasciola spp. The incidence of gastrointestinal worms egg from May-July 2009 in bawean deer at Surabaya zoo were 58%;bawean deer (in the cage) 64%, meanwhile in free ranging were 52%. It didn't give any differences between the two location.

References

Boever,W.J.1986.Artiodactylid Identification, general Husbandry and Parasitic in: M.E Fowler ed Zoo and Wild Animal Medicine.2nd Ed.W.B.Saunders Co..Philadelphia.London.982-983

Koesdarto,S., P.Kusumaningtyas and I.S Yudaniayanti. 2009. Identification of gastrointestinal worms from egg stool samples of Sambar Deer **(*Cervus unicolor*) in** Surabaya Zoo. Proceedings of the International Conference on Animal Health &Human Safety,6-8 Dec.2009.Palm Garden IOI Resort,Putrajaya,Malaysia.pp.25-29.

Semiadi,G.2004. Sifat BiologiRusa Bawean (*Axis Kuhlii*).PusatPenelitianBiologi.Lembaga Ilmu Pengetahuan Indonesia. Bogor.

Varadharajan A. and C. Pythal.1999. Preliminary Investigation on The Parasites of Wild Animals at The Zoological Garden, Thiruvananthapuram, Kerala. Zoo's Print Hournal I-XIV (3-12): 159-164.

EVALUATION OF BEHAVIORAL CHANGES FOR PAIN ASSESSMENT IN SHEEP

Ling CY[1], Chen HC[1*], Sumita S[2]

[1]Faculty of Veterinary Medicine, [2]Faculty of Agriculture,
Universiti Putra Malaysia, 43400 UPM Serdang, Malaysia
**Corresponding author: chen@vet.upm.edu.my*

Keywords: Pain assessment, behavior, sheep

Introduction

The awareness on animal's suffering and welfare has increased in recent years. This dictates the need for better care and humane use of animals for academic purposes. The increased use of sheep as animal models involving invasive surgical procedures raised concerns for inadequate recognition and alleviation of pain in this species. As an animal of prey, sheep has been well-known as a stoic species and do not display overt signs of pain[1]. Nevertheless, in order to provide better treatment following experimental surgery, there is a need for researchers to be able to recognize signs of pain in sheep. Our preliminary analysis on the daily activity budget in sheep showed that postures and locomotion were affected following two invasive surgeries[2]. This study aims to evaluate how specific postures and potential pain-related behaviors change following these two surgeries.

Materials and Methods

Behavioral changes in eight ram lambs that need to undergo two invasive surgeries for a biomedical research were studied. The first surgery involved harvesting of ear cartilage from both ears, and the second surgery involved subcutaneous implantation of engineered autologous tissue on the right flank. Surgeries were performed under ketamine-xylazine-halothane anaesthesia. Analgesia consisted of pre-operative bupivacaine at surgical sites and post-operative meloxicam, 0.2 mg/kg, subcutaneous, once.

Sheep were housed in a 1.5 m raised slatted-floor house with either two or three individuals per pen which measure 2.5 X 2.5 m^2. They were fed twice daily, at 0930 and 1630 hours and were maintained on a diet of sheep pellets, fresh cut grass and water. Sheep were observed between 0800 – 0900, 1100-1500 and 1700-1900 hours on the day before surgery (*Pre-1)* and two days after surgery *(Post-1 and Post-2)*. On the surgery day, sheep were observed for three hours following extubation.

Predefined postures that were studied include head positions during standing statue and recumbency. Proportion of time spent on these postures was determined via scan-sampling at 10 minutes interval and analysed using repeated measures and post-hoc LSD. Potential pain-related behavior studied include head shaking, ear scratching, head rubbing, body rubbing, lip-licking and teeth grinding. Changes in these behaviors were analysed using Wilcoxon signed-rank test. Significance was determined at p-value of 0.05.

Results and Discussion

Following surgery involving the ears, there were no significant changes in the standing postures or side of leaning during sternal recumbency (Table 1). Proportion of time spent with head held lower than withers (head down) during sternal recumbency increased after surgery. Frequency of ear scratching and teeth grinding increased after surgery (Table 2).

Following surgery involving the skin and subcutaneous tissue of the caudal flank, the proportion of time spent standing statue increased, while that for sternal recumbency tended to reduce on the first day after surgery. Out of the total time spent standing statue, the proportion spent with head down increased on the first day after surgery. There was tendency to reduce leaning on the operated side and holding of head above the withers (head up) during sternal recumbency. No significant changes were observed in the frequency of head shaking, ear scratching, head rubbing, body rubbing, lip-licking. Teeth grinding increased on the day of surgery.

Increased frequency of head shaking and ear scratching following surgery of the ear, but not after surgery of the flank, demonstrated that, stimulation-relief activity of the affected anatomical sites may potentially be used as a surrogate for pain. Similarly, postural changes in standing and recumbency were significant following surgery of the flank, but not after surgery of the ears. These surgeries did not restrict movement, thus, the changes could only be explained as an expression to relief or avoid discomfort, or pain following surgery. The increased frequency of head down positions and teeth grinding following both surgeries seemed to suggest that these behaviors may be common expressions of discomfort or pain. Thus, they should be included as parameters to assess pain following surgeries in sheep.

In conclusion, this study had demonstrated specific behavioral and postural changes following surgeries involving specific anatomical sites. This study had also identified common behavioral changes that may be useful for assessment of pain or discomfort in sheep following surgeries.

Acknowledgement

This work was supported by the Ministry of Science, Innovation and Technology, Malaysia under the Grant No: 05-01-04-SF0365

References

National Research Council (1992). Recognition and assessment of pain, stress and distress. In: Recognition and alleviation of pain and distress in laboratory animals. National Academy Press, Washington, DC, pp. 32-45.

Ling CY, HC Chen and S.Sumita (2009). A preliminary observation on changes in daily behavioural activities following surgery in ram lambs. In: Proceedings of the International Conference on Animal Health & Human Safety, 6-8 December, Putrajaya. pp. 224-227.

Table 1: Proportion of time spent in predefined postures before and after two invasive surgeries in eight ram lambs (percentages expressed as mean and standard deviations)

Postures		**1st surgery (Harvest of bilateral ear cartilage)**			**2nd surgery (Tissue implantation on right flank)**		
		Pre-1	***Post-1***	***Post-2***	***Pre-1***	***Post-1***	***Post-2***
Standing statue		8.5±8.5	10.4±10.3	7.4±5.5	13.9±8.2	28.9±12.0*	15.5±16.8
Sternal Recumbency		37.8±20.7	35.1±16.1	42.3±17.4	32.7±15.2	17.6±15.6	33.6±20.2
Standing statue	Head up	84.4±37.4	81.2±36.0	73.3±41.1	86.8±18.9	49.6±36.0*	62.7±40.0
	Head down	1.3±3.4	18.8±36.0	14.2±29.1	13.2±18.9	50.4±36.0*	37.3±40.0
Sternal recumbency	Lean to right	49.9±18.5	52.7±26.0	47.9±13.1	37.2±21.9	25.0±27.7	17.5±30.8
	Lean to left	51.0±19.8	47.4±26.0	52.1±13.1	62.8±21.9	62.5±36.1	82.5±30.8
Sternal recumbency	Head up	48.7±22.2	43.5±21.6	31.4±19.1	43.1±20.0	38.5±37.7	34.4±18.1
	Head down	20.9±7.3	33.7±20.1*	38.9±21.4*	30.1±19.3	27.3±21.0	30.2±11.6
	Head on ground	19.3±19.8	15.5±12.6	22.9±21.0	22.6±27.0	20.3±29.8	29.3±26.3
	Head on flank	11.2±10.2	7.4±6.6	6.8±6.1	4.2±5.9	1.4±3.9	6.1±8.7

*significantly different from baseline (*Pre-1*), p<0.05

Table 2: Specific behaviors with significant changes in ram lambs (n = 8) before and after two surgical procedures. Data are expressed as medians and interquartile range

	1st surgery (Harvest of bilateral ear cartilage)				**2nd surgery (Tissue implantation on right flank)**			
Behaviour	***Pre-1***	***Surgery day***	***Post-1***	***Post-2***	***Pre-1***	***Surgery day***	***Post-1***	***Post-2***
Head shaking	0 (0)	0 (2)	0 (7)	0 (0)	0 (0)	0 (0)	0 (0)	0 (0)
Ear scratching	0 (0)	0 (0)	1 (2)*	0 (2)	0 (0)	0 (0)	0 (0)	0 (0)
Teeth grinding	0 (0)	20 (37)*	0.5 (8)*	0 (1)	0 (2)	2 (18)*	3.5 (20)	1.5 (13)

*significantly different from baseline (*Pre-1*), p<0.05

PRESERVATION, ISOLATION AND DEVELOPMENTAL COMPETENCE *IN VITRO* OF OVINE PREANTRAL FOLLICLES

Bayu Rosadi[1)], M Agus Setiadi[2)], Dondin Sajuthi[3)], Arief Boediono[4)]

[1]Laboratory of Reproduction; Faculty of Animal Husbandry; Jambi University. Email:bayurosadi@yahoo.co.id.
[2]Laboratory of In Vitro Fertilization; Department of Clinic, Reproduction & Pathology; Faculty of Veterinary Medicine; Bogor Agricultural University; Bogor
[3]Primate Research Centre, Bogor Agricultural University; Bogor
[4]Laboratory of Embryology; Department of Anatomy, Physiology & Pharmacology; Faculty of Veterinary Medicine; Bogor Agricultural University; Bogor

Keywords: Follicles isolation, preservation, in vitro culture, ovine

Introduction

The ovarian follicle is the basic structural and functional unit of the mammalian ovary that provides the microenvironment necessary for oocyte growth and maturation. Ovine ovary contains about forty thousands of pre-antral follicles (Rosadi *et al.* 2010) of which only 0.01% ovulates in the reproductive life (Santos *et al.* 2006). In the last decades, many studies have been carried out focusing on this great population of ovarian follicles.Various methods have been developed to isolate and culture pre-antral follicles from several species ovaries (Picton *et al.* 2008). Recently much attention has been given to the short-term preservation at low temperatures and cryopreservation of these follicles in various species. In this study we examined the number and quality of ovine follicles isolated by different methods and post-preservation developmental competence of follicles cultured in vitro.

Materials and Methods

First experiment, follicles isolated from fresh ovaries both mechanically and enzymatically. Ovarian cortex sliced into 1-2 mm^3 cube and incubated in collagenase 1 mg/ml (C1) or collagenase 2 mg/ml (C2) for 15, 30, 45, and 60 minutes. Mechanical isolation (M) held by chopping the cortex tissue into slices using sterile scalpel, then individual follicles harvested using 26 G needle. All follicles isolated were observed under light microscope. Second experiment, preantral follicles were isolated from a) fresh ovaries (control), ovaries were stored at 5^oC for: b) 24 h (T5-24), c) 48 h (T5-48), d) 72 h (T5-72), and vitrified cortex tissue (V). Preantral follicles (220-240 µm) cultured in αMEM supplemented by 5% FCS, 100 mIU/ml r-FSH and ITS (consist of 5µg/ml insulin, 5 µg/ml transferin, 5 ng/ml selenium) up to ovulation stage. The maturation rate of oocytes ovulated were determined by Hoechst 33258 staining.

Results and Discussion

Experiment I shown that C1 and C2 yielded more (P<0.05) follicles than M. Although M consumed longer isolation time but M gave more (P<0.05) intact follicles than C1 and C2 (Table). There was no difference (P>0,.05) between C1 and C2 in follicle number isolated and isolation time.

Table . The yield of mechanical and enzymatical follicles isolation in ovine

Treatment	Ovary number	Average follicle number			Isolation time (min/ovary)
		Intact	Damage	Total	
Mechanical	10	7,3 ± 0,4^b	2,2 ± 0,2^a	9,5 ± 0,2^a	18,4 ± 2,5^b
Collagenase 1 mg/ml	10	1,8 ± 0,2^a	12,5 ± 1,1^b	14,3 ± 1,3^b	7,1 ± 0,8^a
Collagenase 2 mg/ml	10	0,9 ± 0,1^a	11,9 ± 1,7^b	12,8 ± 1,7^b	5,6 ± 0,7^a

Follicle development up to ovulation of T5-24 was equal to control and better (P<0.05) than other treatments. Follicles harvested from vitrified cortex tissue (V) had lower (P<0.05) developmental competence in vitro than control. Ovarium preserved at 5^oC for 48 h resulted in a less number of follicles that reach ovulation stage than others. However, no follicle isolated from T5-72 that developed to ovulation stage.

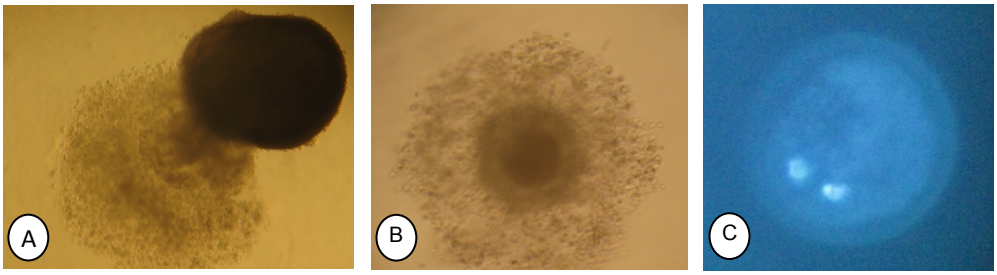

Fig. In vitro culture of pre-antral follicles in ovine. (A) Follicle at ovulation stage, (B) oocytes ovulated by cultured pre-antral follicle, (C) Mature oocyte signed by fluorescence-appearance of two nuclei (arrow).

In all treatment, most of follicles ovulated after 19 to 24 d of culture, more than 80% of oocytes ovulated were mature.

Conclusion

Mechanical isolation gave more intact follicle than enzymatic isolation.Ovine ovaries can be stored at 5°C for 48 h regard to morphology intactness of the pre-antral follicles, of which some maintained its developmental competence to produce mature oocytes. Follicle development up to ovulation of follicles stored at 5°C for 24 h was equal to fresh follicles. Vitrivication of cortex tissue slightly reduced follicles developmental competence in vitro.

References

Picton HM, Harris SE, Muruvi W, and Chambers EL. 2008. The in vitro growth and maturation of follicles *Reproduction* 136: 703–715.

Rosadi B, Setiadi MA, Sajuthi D, Boediono A. 2010. Preservasi ovarium dan pengaruhnya terhadap morfologi folikel domba. *Jurnal Veteriner* (submitted).

Santos SSD, Biondi FC, Cordeiro MS, Miranda MS, Dantas JK, Figueiredo JR, Ohashi OM. 2006. Isolation, follicular density, and culture if preantral follicles of buffalo fetuses of different ages. *Anim Reprod Sci* 95: 1–15.

INTRACYTOPLASMIC SPERM INJECTION (ICSI) USING MOTILE AND IMMOTILE SPERM EXTRACTED FROM PRESERVED RAM EPIDIDYMAL

S. Prastowo[1], M. A. Setiadi[2] and A. Boediono[3]

[1]Departement of Animal Science, Faculty of Agriculture, Sebelas Maret University, Indonesia
[2]Departement of Clinic, Reproduction and Patology, Faculty of Veterinary Medicine, Bogor Agricultural University, Indonesia
[3]Departement of Anatomy, Physiology and Pharmacology,Faculty of Veterinary Medicine, Bogor Agricultural University, Indonesia

Keywords: Motile and immotile sperm, epididymal preservation, ICSI, PN formation

Introduction

The unexpected loss of genetic of farm animal or another species, can be costly in terms of the potential loss of genetically valuable resources. This loss can be reduced by preserving epididymal and use sperm from it for fertilization to continue propagating these valuable genetics. One of the effects of preservation on epididymal sperm was decreasing sperm motility, so sperm can not to be used for normal fertilization. Assisted Reproductive Techniques can help this problem by using ICSI, which did not needed motile sperm. The aim of this research was to study the fertilizing ability of motile and immotile sperm extracted from ram preserved epididymal at 5^0C by using ICSI.

Materials and Methods

Epididymal was preserved at 5^0C for 6 and 9 days in physiological saline solution containing antibiotic. Sperm extracted form epididymal by slicing method, and then evaluated in motility, number of live sperm and sperm with intact membrane. Live sperm determined by Eosin-Nigrosin and intract membrane by short Hypoosmotic Sweeling Test (Pérez-Llano *et al.*, 2001). Ovaries obtained from local abattoirs and oocytes collected by slicing method. Oocytes matured in vitro (IVM) at 38^0C, 5% CO_2 in TCM-199 supplemented with 5% New Born Calf Serum (NBCS), 0.01 mg/ml *Follicel Stimulating Hormone* (FSH) and 10 µl/ml gentamicyn sulfate covered with mineral oil. Only oocytes with extruded polar body I after 20 – 24 hours of IVM (matured oocytes) prepared for ICSI. Sperm prepared by extracted the caudal epididymal. Motile sperm collected from day 6 and immotile sperm from day 9 of preservation. When using immotile sperm for fertilization, only sperm with intact membrane were used for ICSI. ICSI was done by Boediono (2001) procedure. The successful of ICSI was assessed based on the pronuclear (PN) formation (**Figure 1**) after staining with aceto orcein. Percentage of sperm quality and the result of pronuclear formation analyzed using one-way ANOVA. Significance difference tested by Duncan multiple range tests.

Results and Discussion

Result showed (Table 1) that sperm quality at day 6 and 9 preservation in motility, percentage of live sperm and intact membrane was 26.67% and 3.33%, 74.33% and 63.23%, 51,70% and 38.38%, respectively. In fertilizing ability test (Table 2), found that 46.43% oocytes were fertilized and 78.05% oocytes were activated in ICSI using motile preserved epididymal sperm. In another side it was also found 37.21% oocytes were fertilized and 51.16% oocytes were activated in ICSI using immotile preserved epididymal sperm.

Table 1. Sperm quality from preserved epididimal

Sperm Quality	Days of Epididymal Preservation		
	0	6	9
Motility (%)	$(73.54\pm7.27)^a$	$(26.67\pm10.41)^b$	$(3.33\pm1.44)^c$
Live sperm (%)	$(93.45\pm3.59)^a$	$(74.33\pm7.56)^b$	$(63.23\pm3.65)^c$
Intact membrane (%)	$(86.45\pm10.04)^a$	$(51.70\pm8.95)^b$	$(38.38\pm3.72)^{bc}$

[a, b, c] Values with different superscripts in the same row differ significantly (P , 0.05).



Figure 1. Pronuclear formation of oocytes 20 hours after ICSI.(A) No PN formation, (B) 1-PN formation (a = PN), (C) 2-PN formation (a, b = PN)

Table 2. Pronuclear formation of oocytes after fertilization by motile and immotile sperm using ICSI method

Sperm Sources	Oocytes	PN Formation			Oocytes Activated (%)
		0-PN (%)	1-PN (%)	2-PN (%)	
Motile	41	9 (21.95)	13 (31.71)	19 (46.43)	32 (78.05)
Immotile	43	21 (48.84)	6 (13.95)	16 (37.21)	22 (51.16)

The decreasing of sperm quality presumably affected by uncontrolled Reactive Oxigen Species during preservation and called oxidative stress. Oxidative stress result in lipid peroxidation which cause changes in sperm motility, viability and membrane intact (Aitken and Baker 2006). Formation of PN was depending on the concentration of Maturating Promoting Factor (MPF) (Alberio et al., 2001) and gluthatione (GSH) (Yamauchi and Nagai, 1999) in the oocyte cytoplasm. MPF stipulates the formation of female PN and the GSH in male PN.

Conclusions

It was concluded that both of motile and immotile sperm collected from preserved epididimal, have same ability in fertilizing and activating oocytes using ICSI.

References

Aitken RJ, MA Baker. 2006. Oxidative stress, sperm survival and fertility control. Molecular and Cellular Endocrinology 25 : 66 – 69.

Alberio R, V Zakhartchenko, J Motlik, E Wolf. 2001. Mammalian oocyte activation: lessons from the sperm and implication for nuclear transfer. Int. J. Dev. Biol. 45: 797-809.

Boediono A. 2001. Sperm Immobilization Prior to Intracytoplasmic Sperm Injection (ICSI) and Oocyte Activation Improves Early Development of Microfertilized Goat Oocytes. Reprotech 1 : 29–34.

Pérez-Llano B, Jl Lorenzo, P Yenes, A Trejo, P Garcia-Casado. 2001. A Short Hypoosmoic Swelling Test for The Predictioan of Boar Spermatozoa Fertility. Theriogenology 56 : 387–398.

Yamauchi, M. and T. Nagai. 1999. Male Pronuclear Formation in Denuded Porcine Oocytes After In Vitro Maturation in the Presence of Cysteamine. Biol. Reprod. 61: 828–833.

ESTROUS CHARACTERISTIC IN GARUT SHEEP AFTER ESTROUS SINCHRONIZATION USING PROSTAGLANDIN DAN PROGESTERONE-CIDR

M. Agus Setiadi, Aepul

Division Reproduction and Obstetrics
Department of Veterinary Clinic, Reproduction and Pathology
Faculty of Veterinary Medicine-Bogor Agricultural University
Jl. Agatis Kampus IPB Darmaga, Bogor 16680

Keywords: Estrous, synchronization, prostaglandin, progesterone, sheep

Introduction

Garut sheep is an indigenous Indonesian sheep with special interesting characteristic such as big horn performance, weight body condition and high prolificacy. It is therefore to obtain efficient offspring, the farmer to make the effort to breed as soon as possible after parturition. To improve reproductive efficiency, control breeding program is required. One of the main problems associated with controlled breeding is the estimation of the time and degree of estrous response. To make an efficient in breeding program in sheep, induction of estrus is often use treated by several hormones. Hormonal treatment for estrus synchronization is effective in increasing the proportion of females that become pregnant. There are two methods in estrus induction namely by long term administration of a progesterone and by inducing the premature regression of a cyclic corpus luteum by luteolytic agent such prostaglandin F2α (Hafez and Hafez, 2000).The objective of this study was to compare the efficacy two different methods of estrous synchronization on estrous response, onset of induced estrous and estrous duration

Materials and Methods

Twenty five Garut ewes were synchronized using two different hormones application. First groups, 15 Garut ewes were injected intramuscularly 10 mg prostaglandin F2α (Noroprost®, Norbrook) twice with 11 days apart. The second groups, 10 ewes were inserted Controlled Internal Drug Release devices (CIDR) containing progesterone (Eazi-breed CIDR, Pharmacia and Upjohn, New Zealand) for 12 days. All ewes had previously kidded at least once and had their kids weaned. The ewes were fed 0.3 kg concentrate per day. Fresh grass pasture and water were available ad libitum. Estrous detection was done one day after second injection of prostaglandin and after CIDR-removal with the aid ram. Estrous was detected three times a day at (09.00,12.00,16.00) for 2 hours respectively . Number ewes on estrous response, onset of estrous and duration of estrous were recorded. Number of estrous response was recorded as number of sheep that showing standing heat after treatment. Onset of estrus was time interval from second injection of prostaglandin or after CIDR removal to standing heat sign. Duration of estrus was recorded as time interval from first sign standing heat to the last time standing heat. Data of response of estrous from two different treatments were statistically analyzed by using the chi-square test. Average duration of estrus and onset of estrus were analyzed by t student test.

Results and Discussion

Results on estrous response, onset of estrous and estrous duration are set out in Table 1. Estrous was observed in 13 out of 15 ewes in prostaglandin treatment group (86.66%) and in 7 out of 10 ewes in progesterone-CIDR group (70.00%). However, there was no significant difference in the percentage of estrus response between two treatments. Two ewes in PGF2α treatment and three ewes in progesterone-CIDR group did not exhibit estrous within 72 h. The absence of estrus may be due to inadequate estradiol secretion by the ovarian follicles, indicates follicular growth and development (Husein *et al.,* 2005).

Table 1. Estrous characteristic after prostaglandin and progesterone treatment

Treatment	n	Estrous response	Onset to estrous h ± SD	Duration of estrus h ± SD
PGF 2α	15	13(86.66)	32.63 ±3.07	30.95±4.32
CIDR	10	7 (70.00)	38.00 ±7.18	32.85±7.52

The time interval to estrus seems shorter (32.63 ±3.07) h in prostaglandin treatment groups compared with progesterone-CIDR treatment group (38.00 ± 7.18) h although there was not significant difference statistically. Furthermore, its showed that more than 50% ewe exhibited standing heat sign one day either after second injection of prostaglandin or after CIDR removal. However the longest time interval to estrus was 72.30 h after CIDR removal while the shortest onset to estrus was 22.43 h found in

progesterone treatment group. Overall time interval to estrus in prostaglandin treatment was 1-2 days after second injection. These data indicated that time interval to estrus more uniform in prostaglandin group compared with progesterone groups.

The induce estrus duration for prostaglandin and progesterone-CIDR was 30.95±4.32, 32.85±7.52 h, respectively with no significant differences between treatments. Interestingly, several ewes could show longer estrus sign for 2-3 days. It is generally accepted that estradiol hormone is responsible for estrous sign exhibition. The increase in estradiol is related to the development of follicles. It is therefore, further investigation in relation follicle development, time interval to estrus and estrus duration is required.

Conclusion

On the basis of this study, it is concluded that treatment with double injection of prostaglandin and insertion of progesterone-CIDR for 12 days to be equally efficient in synchronizing estrous in Garut sheep with similar estrous characteristic

References

Fonseca, J.F., J.H. Bruschi, I.C.C. Santos, J.H.M. Viana, and A.C.M. Magalhaes. 2005. Induction of estrus in non lactating dairy goats with different estrous synchroni protocol. Anim. Reprod. Sci. 85: 117-124.

Hefez, E.S.E. and B. Hafez. 2000. Reproduction in farms animals. 7th ed. Lippincott Williams and Wilkins. Philadelphia.

Husein, M.Q., M.M. Ababneh, and S.G. Hadad. 2005. The effects of progesterone priming on reproductive performance of GnRH-PGF2α-treated anestrous goats. Reprod. Nutr. Dev. 45: 689-698

Romano, J.E. 2004. Synchronization of estrus using CIDR, FGA, or MAP intravaginal pessaries during breeding season in Nubian goats. Small Ruminant Research.55: 15-19.

THE SPERM MORPHOLOGICAL ASSESSMENT OF BULL SEMEN AT SEVERAL ARTIFICIAL INSEMINATION CENTERS IN INDONESIA

R. I. Arifiantini[1)], B. Purwantara[1)], and M. Riyadhi[1,2)]

[1] Division of Reproduction and Obstectric, Department of Clinic, Reproduction and Pathology, Faculty of Veterinary Medicine, Bogor Agricultural University, Darmaga, Bogor 16680 Indonesia.
Iis.arifiantinipurna@gmail.com
[2]Livestock Study Program, Faculty of Agriculture, Lambung Mangkurat University, Banjar baru South Kalimantan

Introduction

Artificial insemination (AI) was the first great biotechnology applied to improve reproduction and genetics of farm animals. It has had an enormous impact worldwide in many species, particularly in cattle. Male fertility is an important factor in bovine reproduction since a single bull is generally bred to numerous cows. The breeding soundness evaluation (BSE) is a method of evaluating the potential of a bull to be used as a herd sires (Chenoweth et al., 1992). The BSE consists of evaluating scrotal circumference (SC), semen quality, physical soundness, and overall health of the bull.

Breeding soundness evaluation (BSE), were used to identify individual problems of the bull fertility. In general BSE consists of three parts; physical evaluation (evaluation on external genital organs and rectal exploration), measurement of scrotum circumference and semen analysis. Semen analysis commonly included in BSE are sperm concentration, sperm motility and sperm morphology (Bagley, 2009; Shipley, 1999; LeaMaster and Du Ponte, 2007; Barham and Pennington, 2009).

Since 1976 until 1998, Indonesia has two national AI centers; each is located at Lembang-West Java and Singosari-East Java. In the year 2000, owing to the Nation's decentralization of developmental efforts, Fifteen regional AI centre were established in several provinces.

Assessments of sperm motility and sperm concentration have been well developed in Indonesia; several AI centers are equipped with computerized instruments. On the other hand, assessments on sperm morphology have not been done as much, although many studies had demonstrated the effects of abnormal sperm morphology to infertility (Chenoweth, 2005; Saacke, 2008). An accurate morphological screening of the ejaculates allows elimination of bulls with low fertility prior to the progeny testing program and preservation of semen, thus entitling AI centers to major cost savings.

Considering the high numbers of AI centers (AIC) in Indonesia and the shortage of skill to evaluate sperm morphology, this study was conducted to evaluate bull sperm morphology by focusing on the primary sperm abnormalities at several AI centers in Indonesia.

Materials and Methods

Semen sample

Semen sample collected from 14 AI centers in Indonesia, a total of 164 cattle bulls used in the study. Staining and evaluations of sperm abnormality were conducted at Reproductive Rehabilitation Unit Laboratory, Faculty of Veterinary Medicine, Bogor Agricultural University.

Sample Preparation and staining

Fresh semen collections and smears preparations were performed from bull in AI centers, the samples were then delivered to the research laboratory in Bogor. Smeared samples were stained with carbolfuchsin-eosin according to the method described by Williams in 1920 and modified by Lagerlof in 1934 (Kavak *et al.,* 2004). Five hundred sperm were counted on each smear using a light microscope at 400x magnification; sperm morphology was examined by looking at the head abnormalities. All types of sperm abnormality from 500 cells on each sample. were recorded and classified. The classification of primary sperm abnormalities was based on the findings at the time of assessment (Barth and Oko, 1989).

Results and Discussion

In total, 164 bull sperm morphology were performed: 42.68% (70/164) on Simmental bulls, Limousine 18.29% (30/164), Bali and FH bull was 13.41% (22/164) and the rest from several crossbred bull.

In general, without considering the individual factors or the sperm abnormality types, sperm abnormality level of bulls at AI centers in Indonesia was low (3.2±1.95%). In this study, among the breeds consisting of more than 10 bulls, the highest incidence of primary sperm abnormalities was found in Simmental bulls (4.8±4.2%); this was significantly higher ($p<0.05$) than those in Bali bulls (1.6±1.7%). Primary sperm abnormality levels were not significantly different between Simmental, Limousine, and Brahman bulls; likewise, no significant differences on primary sperm abnormality levels were found

between Limousine, Brahman, and Bali bulls. Pear shaped was the most frequently type of abnormality found on examined samples (2.24±2.94%); while double head was the lowest (0.01±0.04%).

It was recorded that 77.46% samples had low primary sperm abnormalities (<5%), while the high level of primary sperm abnormalities (>15%) was found in 5.63% samples. Previous studies in humans demonstrated sperm cell morphology was an important predictor of male fertility, yielding lower fertilization rates of sperm samples containing higher proportions of morphologically abnormal spermatozoa. Likewise, poor spermatozoa morphology was correlated to the decreased fertility potential in bovine (Al- Al-Makhzoomi *et al.,* 2008).

Sperm abnormality rate according to Ax *et al.,* (2000) is 20%; the sperm abnormality rate is the total number of sperm abnormalities, including the primary and secondary abnormalities. Focus of this study was primary sperm abnormalities; this was based on the consideration that secondary sperm abnormalities affecting the tail could be self-selected during sperm motility examination. Sperm with tail abnormalities, such as coiled or bent tails automatically do not show a progressive movement. Secondary sperm abnormalities are usually due to environmental factors and are easy to fix. On the other hand, primary sperm abnormalities affecting the head cannot be detected during sperm motility evaluation; sperm with microcephalus, narrow head, or narrow at the base may have a more progressive movement than normal sperm because of their thinner shape.

A raise question: what is the allowed percentage of primary sperm abnormalities? Since there were no reports on the minimum or maximum percentage of primer sperm abnormality in cattle bull and considering of 20% maximum sperm abnormality rate Ax *et al.* 2000) and if we referred to Al-Makhzoomi *et al.,* (2008) the primary of sperm abnormality more than 10% will affect the fertility, in this research we found 11 bulls (6,7%) which did not have qualified semen for further processing into frozen semen (data not showed)

Base on our finding, that the number of sperm abnormality in general was low but, when we evaluate individually 11 bulls are unqualified to process, we concluded that sperm morphology should be evaluated individually prior to production and distribution.

Acknowledgement

This study was supported by Directorate of Higher Education competency grant number 219/SP2H/PP/DP2M/V/2009 to Iis Arifiantini. We acknowledge all participated AI centers to sending fresh semen samples for the study materials

References

Ax RL, MR Dally, BA Didion, RW Lenz, CC Love, DD Varner, BkHafez and ME Bellin, 2000. Semen Evaluation In : Hafez ESE and B Hafez, editor. Reproduction in Farm Animal. 7th ed. USA: Lippincot Wiliams and Wilkins.

Bagley CV. 2009. Breeding Soundness Examination Of Rams Cooperative Extension work Utah State University http://extension. usu.edu/files/publications/factsheet/ AH_Sheep_02.pdf (1 November 2009).

Barham B and JA Pennington. Breeding Soundness Evaluation for Beef and Dairy Bulls http://www.uaex.edu/other_areas/publications/pdf/fsa-3046.pdf (1 November 2009).

Barth AD and RJ Oko. 1989. Abnormal morphology of bovine sperm. Iowa: Iowa State University Press.

Chenoweth PJ. 2005. Genetic Sperm Defect. Theriogenology 64; 457-468.

Kavak A, *et al.* 2004. Sperm morphology in Estonian and Tori breed stallions. *Act. Vet. Scan.* 45:11-18.

LeaMaster BR and MW Du Ponte. 2007. Bull Power: Examination of Beef Cattle Bulls for Breeding Soundness. Department of Human Nutrition, Food and Animal Sciences College of Tropical Agriculture and Human Resources (CTAHR) http://www2.ctahr.hawaii.edu/oc/freepubs/pdf/LM-17.pdf(1 November 2009).

Al-Makhzoomi, A, N Lundeheim, M Haard and H Rodrıguez-Martınez. 2008. Sperm morphology and fertility of progeny-tested AI dairy bulls in Sweden. *Theriogenology* 70: 682–691Saacke RG. 2008. Sperm morphology: Its relevance to compensable and uncompressible traits in semen. Theriogenology 70;473–478.

Shipley CF. 1999. Breeding soundness examination of the boar. *Swine Health Prod.* 7: 117–120.

EFFECTS OF ANTI-OXIDANT ADDITIVES ON GOAT SEMEN QUALITY AFTER CRYOPRESERVATION

S.W. Naing[1], H. Wahid[1], K. Mohd Azam[3], Y. Rosnina[1], A.B. Zuki[2]

[1] Department of Veterinary Clinical Studies, Faculty of Veterinary Medicine, Universiti Putra Malaysia, 43400 UPM, Serdang, Selangor Darul Ehsan, Malaysia;
[2] Department of Preclinical Veterinary Sciences, Faculty of Veterinary Medicine, Universiti Putra Malaysia, 43400 UPM, Serdang, Selangor Darul Ehsan, Malaysia;
[3] Faculty of Veterinary Medicine, Universiti Malaysia Kelantan, Jalan Pengkalan Chepa, 16100 Kota Bharu, Kelantan / ar-Raudhah Biotech Farm Sdn. Bhd, Kampung Bunga Raya 48050 Kuang, Selangor, Malaysia.

Keywords: Goat, semen, cryopreservation, antioxidant

Introduction

For the maintenance of sperm motility and viability, anti-oxidant plays important role to protect against lipid peroxidation by removing superoxide anion radical production (1, 2). The aim of this study was to determine the influence of four anti-oxidants (alanine, glycine, glutamine, and cysteine) additives at the concentration of 20 mM in trehalose based extender on goat semen quality after cryopreservation.

Materials and Methods

A total of six Boer goats (body weights from 110 to 125 kg) were used as sperm donors. Semen was collected by using an artificial vagina twice a week. Tris-based extender was used as a cooling extender, containing 250 mM tris, 88.49 mM citric acid, and 69.38 mM glucose. The freezing extender consisted of tris-based extender plus glycerol 7% (v/v), and egg yolk 18% (v/v), and trehalose (198.24 mM). Four anti-oxidants at the concentration of 20 mM were added to the freezing extenders. An extender containing no anti-oxidant additive was used as control.

Immediately after collection, the ejaculates were assessed for volume, colour, consistency, mass activity, sperm concentration, sperm morphology, and percentage of motile spermatozoa (3). Only ejaculates between one and two mL volume with a concentration of greater than 2.5 x 10^9 sperm/mL having >75% progressively motile sperm and >85% of the sperm with normal morphology were selected for cryopreservation. After initial evaluation, semen was diluted with washing solution and then centrifuged at 1500 x g for 3 min to remove seminal plasma. The supernatant was removed and semen dilution was performed by two step dilution methods. Semen was diluted with cooling extenders and incubated at room temperature for 5-10 min. Subsequently, the extended semen were placed in a cooling chamber at 5˚C and maintained for 2.5 hours. Each of the extended semen was diluted in the freezing extender and kept for 30 min. Final concentration was adjusted to 150 x 10^6 spermatozoa for a straw. The sperm suspension was loaded into 0.25 ml plastic straws immediately. The straws were horizontally placed on an aluminium rack and frozen in liquid nitrogen vapour, 5 cm above the surface of liquid nitrogen for 7 min. Subsequently, straws were immersed into the liquid nitrogen for storage. After 2 days, frozen straws were thawed individually at 37˚C for 30 seconds in a water bath for evaluation (total motility, forward motility, intact acrosome, live, and normal spermatozoa). One-way analysis of variance, followed by the Tukey's post hoc test was used to determine the significance of the parameters measured.

Results and Discussion

There were no differences (P>0.05) on all semen quality parameters during the cooling step (Figure 1). After freezing of Boer goat semen (Figure 2), cysteine addition at the concentration of 20 mM led to a significantly higher total motility, forward motility, acrosome integrity and live spermatozoa percentage compared to the other amino acids. However, differences were not detected between cysteine group and control group. Normal spermatozoa percentage was not affected by the different anti-oxidants.

Cysteine, also known as a precursor of intracellular glutathione biosynthesis, plays an important role as an anti-oxidant to protect membrane lipids and proteins. Cysteine could prevent hydrogen peroxide mediated loss of sperm motility in frozen thaw semen (4). Although, anti-oxidants could contribute to the improvement of semen extenders in semen cryopreservation process, the effective concentrations and types of anti-oxidants varied on species differences. These effects may be related to the differences in susceptibility to lipid peroxidation among species, breeds, individual variation, and seminal plasma composition.

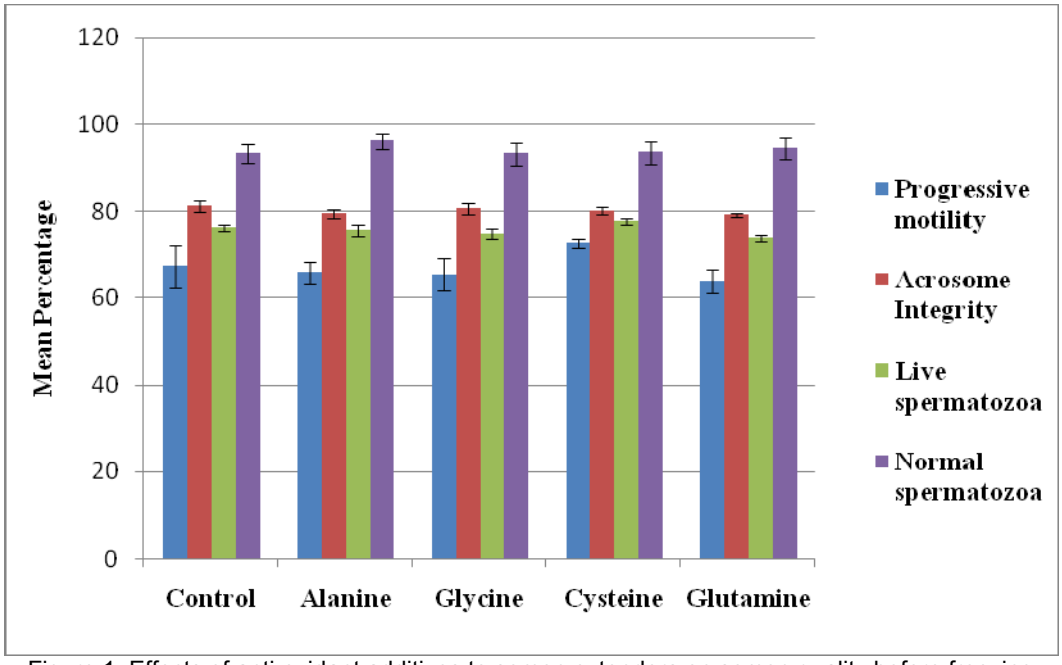

Figure 1: Effects of anti-oxidant additives to semen extenders on semen quality before freezing

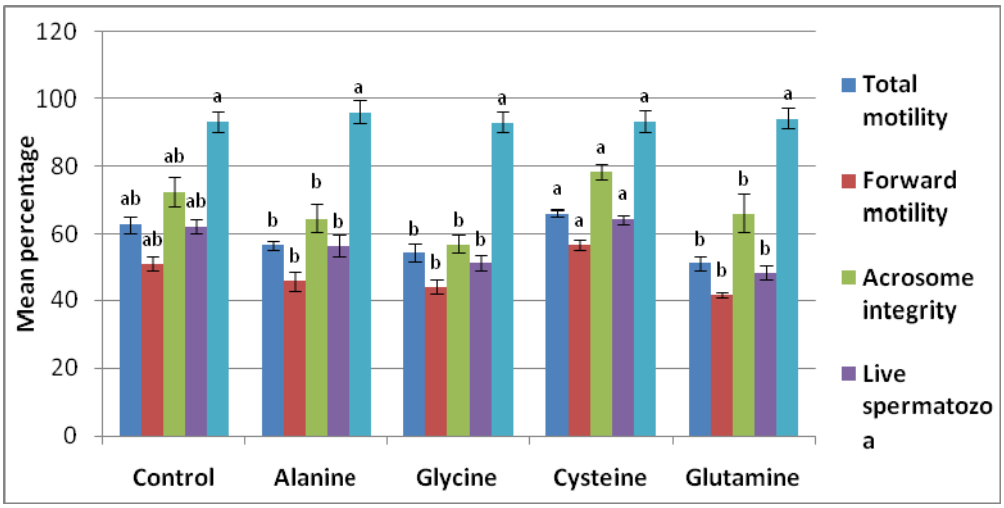

Figure 2: Effects of anti-oxidant additives to semen extenders on semen quality after thawing. Different letters (a, b) indicate significant differences (P<0.05)

Conclusion

Addition of 20 mM cysteine in freezing extender significantly improved total motility, forward motility, acrosome integrity and live spermatozoa percentage compared to the other amino acids. However, future studies are needed to find their optimal anti-oxidant concentrations to improve post-thaw sperm quality.

This study is supported by Agro-Biotechnology Institute, Ministry of Science Technology and Innovation, Malaysia (Research Project 5487703). Our special thanks to ar-Raudhah Biotech Farm Sdn. Bhd., Kampung Bunga Raya, 48050 Kuang, Selangor, and various persons for helping in this study.

References

Atessahin, A., Bucak, M.N., Tuncer, P.B., Kizil, M., 2008. Effects of anti-oxidant additives on microscopic and oxidative parameters of Angora goat semen following the freeze-thawing process. Small Ruminant Research 77, 38-44.

Bucak, M.N., Atessahin, A., & Yüce, A., 2008. Effect of anti-oxidants and oxidative stress parameters on ram semen after the freeze-thawing process. Small Ruminant Research, 75(2-3), 128-134.

Evans, G., Maxwell, W.M.C., 1987. In: Salamon's Artificial Insemination of Sheep and Goat (Ed.: Maxwell, W.M.C.). Butterworths, Sydney.

El-Sheshtawy, R.I., El-Sisy, G.A., El-Nattat, W.S., 2008. Use of selected amino acids to improve buffalo bull semen cryopreservation. Global Veterinaria, 2 (4), 146-150.

REPRODUCTIVE POTENCY AND EFFORT TO BREEDING SPOTTED BUFFALO IN TANA TORAJA

Yulnawati[1], H. Maheswari[2], A. Boediono[2], M. Rizal[3], Herdis[4]

[1] RC. Biotechnology, LIPI, Jl. Raya Bogor km. 46, Cibinong, 16911,
[2] Dept of Anatomy, Physiology and Pharmacology, Faculty of Veterinary Medicine IPB,
Jl. Agatis IPB Campus, Darmaga, Bogor, 16680
[3] Dept. of Animal Husbandary, Faculty of Agriculture, Pattimura University,
Jl. Ir. M. Putuhena, Kampus Pokka, Ambon
[4] BPPT , Jl. MH. Thamrin Kav. 8, Jakarta

Keywords: Epididymal Sperm, Artificial Insemination, Spotted Buffalo

Introduction

Indonesia has so many biodiversity since we lived in equatorial with tropical climate. Almost all of them need special attention to prevent from extinction. One of our biodiversity is spotted buffalo, with their natural habitat in Tana Toraja, South Sulawesi. Local people used the male spotted buffalo to be sacrificed in funeral ceremony. They also prevent their animals to do reproductive activity, because of false perception about natural mating. They believe that natural mating will give negative effect to their animals, like decreasing body size, become wild and uncontrolled. It affect the decreasing of spotted buffalo population each year.

To prevent the spotted buffalo from extinction, we can apply reproductive technology without disturb Toraja people and their social culture. We can utilize epididymal tissue from male spotted buffalo which sacrificed in funeral ceremony as a potencial gamete (sperm) source. Due to recent research in other kind of mammals, sperm collected from epididymal tissue has same motility and fertility with ejaculated sperm Furthermore, epididymal sperm could be processed become liquid or freeze semen before used it in artificial insemination (AI), in vitro embryo production (IVEP) or intra cytoplasmic insemination (ICSI) program. All of the offspring will bring half of genetic code from their paternal, it means there is a great chance to produce more spotted buffalo in the next future.

Materials and Methods

Sperm was collected from ejaculation using articial vagina or cauda epididymal tissues by slicing and pressuring method. The quality of sperm including concentration, progressive motility, live cells, abnormality and membrane integrity were analyzed using light microscope with 40x objective lens.

Results and Discussion

Generally, sperm quality, both from ejaculate or epididymal were showed the same result (Table 1). But, epididymal sperm concentration from spotted buffalo (10.445 x 10^6 sperm/ml) were higher than ejaculate (1.200 – 2.695 x 10^6 sperm/ml). This is related to the function of cauda epididymal as a sperm storage before ejaculated and the sperm did not get any supplementation from acessories gland, so, its concentration become very crowded.

Table 1. The quality of ejaculate versus epididymal sperm of spotted and solid buffalo

Parameters	Ejaculated of spotted buffalo (Batossama 1985)	Ejaculated of solid buffalo (Yulnawati *et al.,* 2009)	Epididymal sperm of spotted buffalo (Yulnawati *et al.,* 2008)
Concentration (x 10^6 sperm/ml)	1.200 ± 0.5	2.695 ± 1045	10.445 ± 43.6
Progressive Motility (%)	74 ± 4.8	70.0 ± 0.0	65.0 ± 0.0
Live Cell (%)	-	73.0 ± 1.0	79.3 ± 1.3
Abnormality (%)	15.06 ± 4.93	6.5 ± 1.5	15.0 ± 2.2
Membrane Integrity (MI; %)	-	77.5 ± 1.5	80.8 ± 0.4

The data showed that there were no significant different between the quality of sperm, both from ejaculate of epididymal of spotted buffalo. They have same abnormality rate (15.06 vs 15.0 % in ejaculate and epididymal sperm). Due to its farmering system, that farmer do not allowed their buffalo doing reproductive activity normally, so we can understand why there were so many abnormality of sperm both in ejaculate or epididymal tissue. But, referring to Ax *et al.*, 2000, this result were still suitable for AI since the bordered of abnormality rate was 15%.

Data in Table 1 also showed that there were no significant different between the quality of sperm, both from spotted or solid buffalo. It means spotted or solid buffalo have same reproductive potency and suitable for artificial insemination, as an application of assissted reproductive technology. These data also made us believe that there is a way to increase spotted buffalo population and prevent them from extinction with solve the problem from the male side.

The first AI application in spotted buffalo was reported by Toelihere, 1975. He got 57.9% of conception using ejaculated sperm. But all of the offspring were solid buffaloes. Batossama (1985) conducted the research in order to increase the quality of freeze-thawed spotted buffalo epididymal sperm. The result shwoed that the motility of post thawed ejaculated sperm was 50 ± 6.5 % and still suitable for AI. More of the baby that delivered from that program were have white colour in all of their skin (albino). This result suggested that there is a specific pattern in coat color inheritance in spotted buffalo.

Until now, there is a big homework for us to answer the question, how to increase the spotted buffalo population? From the one side in reproductive area, we found that epididymal sperm has big potency to be used in producing offspring. But we also have to study the pattern of spotted coat color inheritence, that also play main role to increase the spotted buffalo in the next future. The preliminary research that combined the breeding and genetic area of spotted buffalo has been conducted by our group in order to prevent them from extinction.

Conclusion

An effort to increase the spotted buffalo population should be conducted by utilize the genetic material (epididymal tissue) from funeral ceremony. Our result showed that the sperm quality from cauda epididymal has same quality with ejaculated sperm, both from spotted or solid buffalo. Futhermore, we will also study about breeding and genetic pattern of spotted coat color that inherited from paternal side to the offsprings.

References

Ax, R.L., Dally M., Didion B.A., Lenz R.W., Love C.C., Varner D.D., Hafez B., Bellin M. E. 2000. *Semen Evaluation.* In: Hafez E.S.E. & Hafez B.. *Reproduction in Farm Animals*.7th Ed. Baltimore: Lippincott Williams & Wilkins pp 365-375.

Batossama J.T. 1985. The application of artificial insemination for spotted buffalo conservation. Dissertation. Bogor Agricultural University.

Yulnawati, Herdis, Maheshwari H., Rizal M. 2008. The quality of epididymal sperm with addition of raffinose as external cryoprotectant. *JITV* 13(1): 30-34.

Yulnawati, Gunawan M., Herdis, Maheshwari H., Rizal M. 2009. The role of sugars as external cryoprotectant in maintain the quality of freeze-thawed sperm of swamp buffalo. Proceeding "The Potency and Development of Farm in Maluku in Order to Reach the Surplus of Meat and Milk Production". Ambon, March 2, 2009. pp 236-250.

REPAIR OF SPIRAL FRACTURE OF THE LEFT FEMUR IN AN ETTAWA GOAT USING COMBINATION MEDULLARY, TRANSSEGMENTAL PINNING AND WIRING

Dhirgo Adji

Department of Surgery and Radiology, Faculty of Veterinary Medicine, Gadjah Mada University, Fauna Street No.2, Karang Malang, Yogyakarta, Indonesia 55281. Phone. 0274 560862, fax 0274 560861, e-mail : dhirgo_adji@yahoo.com.

Keywords: Spiral fracture, Steinmann pin, medullary pinning, transsegmental pinning, wiring

Introduction

Ettawa goats are firstly located in the village of Donorejo, Kaligesing, Purworejo, Central Java. Goats were crossed-mate with local goats in Kaligesing. Until now Ettawa goat known as Peranakan Etawa (PE) genuine goat race Kaligesing District, the District of Purworejo. Ettawa goat are preferred by many people, especially around Central Java, including Yogyakarta. The goat has spread rapidly to various areas in the district of Purworejo even down to the outside of Purworejo such as Kulon Progo, Kendal and Sidoarjo, East Java. Ettawa goat typically in the form of a convex face, the long-eared, high posture between 90-110 cm, short, slender horns. This type of goat easily thrive in the cold air, like the area around the mountains or plateaus. Goat of this type have a large body of varied plumage, white stripes, red brown, black spot or a combination of all three. There is a thick and long hair at the back. Because it is very rare type of goat, people usually take an Ettawa goat as a pet.

In the recent years, many diseases of Ettawa goat have been examined and treated at the Gadjah Mada, Veterinary Clinic, including cases that require surgery. In January 19 th, 2010, a male Ettawa goat was assessed in the Department of Surgery and Radiology, Faculty of Veterinary Medicine, Gadjah Mada University because it has a left rear limb fracture. Completely analysis of this goat including radiographic showed that the goat has a closed spiral fracture at the shaft of the left rear femur, and need a surgery treatment.

Materials and Methods

A one year old, 55 kg, male purebreed Ettawa goat was examined for nonweight bearing lameness of the left hind of 3 days duration. Findings on physical examination included a temperature 39.8°C, tachypnea (78x/ min), tachycardia (104x/ min) and depression. Swelling and crepitation were noted on palpation of the mid left femur region. Radiographs of the left femur revealed a long spiral fracture of the mid diaphiseal portion of the left femur with caudo lateral displacement of the distal fracture fragment (Figure 1).



Fig. 1. Spiral type fracture of the shaft of left femur (Arrow)

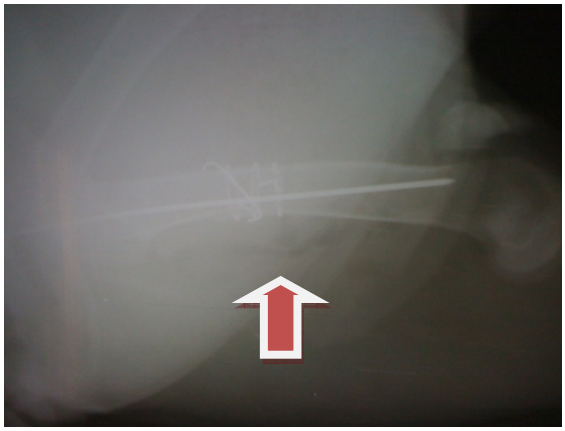

Fig.2. Spiral fracture of left femur after reduction and fixation

Ketamine hydrochloride (15 mg/kg BW) and Xylazine hydrochloride (2 mg/kg BW) were used as general anesthesia. The goat was positioned in dorsal recumbency, and affected limb was tied to an over hanging frame with tension to facilitate fracture reduction. The limb was clipped and aseptically prepared for surgery. The femur was approached laterally by a craniolateral incision through the skin and subcutaneous tissue directly over the area of contact between the fascia lata and the cranial edge of the biceps femoris. The exposed fascia lata was incised along this same line. Retraction of fascia lata and the

biceps femoris exposes the fracture. Cranial retraction of the vastus lateralis muscle and caudal retraction of the biceps femoris revealed the shaft of the femur. The proximal fragment extends cranially, the distal fragment extent caudally. The area of surgery was suctioned dry, the fragment ends were brought into the incision area and were inspected for small fissures that might split when manipulated. Because the type of fracture was spiral, we assumed that reduction and stabilization will become unstable. Two cerclage wires were reinforced these areas. An intramedullary pin was selected that will pass into the distal fragment. The pin was introduced along the medial face of the trochanter, into the trochanteric fossa. In this condition, because the size of the pin was too small, we afraid that wiring and pinning were not strong enough. Transsegmental pin was also inserted as a nail to strengthen fixation between fragments. Steinmann pin was inserted into the distal fragment cross to the proximal fragment with 90° angle. After fixation, all muscles were then returned to the its original place and stiched using chromic catgut 00.

Discussion

Surgery technique to solve many bone defects is a good challenge. Early evaluation of fracture healing could have important concequences for animals with normal and impaired fracture healing. Because the period of nonweightbearing after a fracture has been shown to influence the amount of bone loss (Van der Wiel et al., 1994). Early mobilization and weightbearing are among the goals of fracture treatment. More over, early detection of impaired healing can lead to intervention aimed at the prevention of delayed or nonunions. The use of the Steinmann Pin here is not good enough because the fracture was unstable and the diameter size of the pin was too small. Brinker (1971) said that intramedullary pinning should be reserved primarily for stable fractures. It may be used on unstable fractures only with supplemental fixation, such as Kirschner splint or Thomas splint. In this case, we used 3 cerclage wires placed on the proximal and caudal sharp-end of fracture segment to strenghten and stabilize the fracture connection. We still need to consider whether the connection is strong enough. To further strengthen the connection, then we use a small Steinmann pin that transsegmentally inserted between fragments (Figure 2). Restrict activity of the animal during the healing period is one point that we should do. The management of fracture of the femur was done without external fixation or splint. As our experienced, external fixation method will increased psychological stress in laboratory animals (Adji, 2008). We didn't use any splint method because the splint can disturb the goat when he wanted to stand up. The goat began to bear weight on the affected limb after recovery from anesthesia, but he was lame at the walk. The goat was then restricted in a small pen for eight weeks and examined eight weeks after surgery, when he was walking normally on the affected limb. Although the goat could normally walk and the wound of the skin was totally heal, we still need more time evaluation for the best result.Twelve weeks after surgery when we examined the condition of the goat, we saw the goat can normally walk on the affected limb, good attitude and also good in eating and drinking. Because the owner objected to the additional cost, we can not bring the got to our clinic to evaluate the condition of the fracture. We assumed that there were a good union of the fracture just because the goat can normally walk.The intrameduller pin was then removed easily from the limb by hand after aseptically cleaning the pin and surrounding skin. This decision was the same as what Leighton (1994) said that intramedullary pin should be removed when the fracture has reached the stage of clinical union. We didn't removed the transsegmental pin and wires and let it to stay for all of the goat's life. For the best result, the goat was then confined to a small pen for an additional 2 weeks. Two months later, the goat was walking normally without difficulty.

Conclusion

Unstable fracture such as spiral type fracture can only be treated by open reduction and internal fixation. The use of combination of intramedullary pin, cerclage wire and transsegmental pin can make the fragment to be stable. Restrict activity of the animal during healing period was an supporting key to a better recovery.

References

Adji, D., 2008. The evaluation of fracture Healing on Radius after Stabilizad using Intrameduller and external Fixation. Gadjah Mada Veterinary Grand Research.

Brinker,W.O., 1971. Small Animal Orthopedics. Piblished by Continuing Education Service, Michigan State University.

Leighton, R.L., 1994. Small Animal Orthopedics. Wolfe, London, St. Louis, Boston, Chicago, Philadelphia, Sydney, Toronto.3.23-3.25.

Piermatteii, D.L and Greeley, R.G., 1966. An Atlas of Surgical Approaches to the Bones of the Dog and Cat. WB. Saunders Company, Philadelphia and London, 104-105.

Van der wiel, h.e., lips, p., nauta, j, 1994. Loss of bone in the proximal part of the femur following unstable fractures of the leg. J. Bone joint surg. 76 a:230-236.

THE VALUE OF QUALITY PROBLEM-ORIENTATED VETERINARY RECORDS IN TEACHING VETERINARY HOSPITALS – A CASE OF CERVICAL SPONDYLOPATHY IN A DOBERMAN DOG

H. Rashid-Ibrahim

DVM (UPM), PG Dip. Sm. Anim. Surg (Guelph, Canada), PhD (Bristol, England)

Associate Professor in Vet Orthopaedic Surgery – Head of Surgery UPM-Vet Hosp
Dept of Veterinary Clinical Studies, Faculty of Veterinary Medicine, Universiti Putra Malaysia
43400 UPM, Serdang, Selangor, MALAYSIA

Keywords: Veterinary medical records, POVMR, SOAP, veterinary teaching hospital, information gathering, patient-focused, problem-orientated, cervical spondylopathy, wobbler, conservative, surgical, lag-screw fixation, bone graft, follow-up examination.

Introduction

Problem Orientated Medical Record (POMR) was first introduced in 1968 by Lawrence Weed in the USA as "Medical Records that Guide and Teach" which are patient focused and problem orientated. The case record system had since then been used at Veterinary Teaching Schools in North America (USA and Canada) as Problem Orientated Veterinary Medical Record (POVMR). Elsewhere its use had been very limited, and only recently POVMR had been adopted in Veterinary Teaching Hospitals in other regions. At Universiti Putra Malaysia Universiti Veterinary Hospital (UPM-UVH) we had embarked on its use since 1974. The purpose of a POVMR had been for teaching and learning, communication among members of the medical and surgical teams, and as legal records. POVMR organizes case information so it can be recorded, easily understood by others, and defended in a court of law. It is the method many veterinarians use to do this and has been in place for more than 40 years (Weed, 1968).

Materials and Methods

A veterinary medical record provides documentary evidence which contains the information about a patient, or herd of animals, including laboratory reports, imaging/radiographs and clinical notes (Houston *et al*., 2005). The American Animal Hospital Association (AAHA) maintains standards for medical records of AAHA-approved hospitals in USA and Canada. The teaching and learning had emphasised a systematic, analytic approach, which help you learn "patterns" (a function of experience and knowledge base) of common diseases which occur commonly, review (learn) the cases, integrate – problems and causes, maintain focus on the patient and related problems, and finally student evaluation e.g. in their clinical training blocks.

POVMR is a part of an attempt to address the most common problems in diagnosis and case management which are inadequate hypothesis generation, and inattention or misinterpretation of findings of history, physical examination, laboratory data, etc. Errors could have resulted in Premature Closure where the clinician stops generating new hypotheses before the correct diagnosis has been added to the list of Differential Diagnosis, and the Most Common Interpretive Error where over-interpretation or misinterpretation of findings in light of suspected disease.

The two main components of POVMR are Master Problem List (MPL), and SOAP (Subjective data, Objective data, Analysis, Plan). The POVMR concept involve the two above components whereby the MPL is always kept at the front of the record – "front and center" where the MPL is updated and revised DAILY or (or at each submission).

A PROBLEM is anything that potentially threatens the health of the animal *(or herd)* and may require medical attention *(at least eventually)*. A problem should undergo four processes *viz*. indentification, hypothesise how to solve, start treatment - diagnostic and therapeutic – based on hypothesis, and finaaly prove/disprove hypothesis through critical evaluation of the results. Hence the POVMR could be made easy in four steps i.e. **Step One**: Information Gathering (Subjective Information, Objective Information); **Step Two**: Problem Identification and Analysis/Assessment; **Step Three**: Planning (1) Diagnostic Plans (Dx), (2) Therapeutic Plans (Rx), (3) Client Education Plans (CE), and **Step Four**: Follow-up.

Every problem had to be clerked and **SOAP**ed in the Progress Notes daily at the end of the previous day. The Subjective Information (S): would be entered i.e. attitude, appetite, activity, improving? Unchanged? - include client's observations during presentation. In the Objective Information (O): the students/clinicians would Summarise the measurable clinical data (fever? laboratory? radiology? etc.). Then Analysis/Assessment (A) of the problem is made thoroughly, the most valuable tool in the making of a doctor during clinical training. The clinical logic is used to define and analyse/assess (A)

each problem (Gibbon, 2009). Each assessment has three components *viz.* General pathophysiologic mechanisms for the problem, Pathophysiologic mechanisms likely for THIS case, and Differential Diagnoses for THIS problem. Hence Problem Analysis/Assessment would require the use of critical thinking and integration which is necessary during quality training of clinical doctors.

These records should capture your THOUGHT PROCESSES, and answer these questions – Can you localise the disease? (e.g. to an organ system?); Is the signalment important or useful? (species, breed, age, sex); Duration and Course? Are other animals affected? Was there previous treatment/response? Has your understanding of the problems changed? Notably changed in light of new data; and how can you pull the case or problems together?

The subsequent plan (P) should help rule in/rule out your primary Differential diagnosis, or treat the patient. Then the diagnostic, therapeutic, and client education plans (P) would be instituted to address each problem. The initial plan can include specific diagnostic tests, specific treatments, doing nothing (wait & see), client communication plans (including questions), and the proposed plan may be stated as a sequence of plans or possible courses of actions.

Table 1. Mnemonic of diagnostic categories

	Disease Category	Example Diagnoses
D	Degenerative	Osteoarthritis, senile Degeneration
	Developmental	Shunts, organ agenesis, Hypoplasia
A	Anomalous	
	Autoimmune	
	Atmospheric	Environmental parameters, Microhabitat
	Allergic	
M	Metabolic	Hormonal disorders, enzyme disorders, gout, lipidosis, Xanthomatosis
	Mechanical	Thermal, pressure, radiation, Obstruction
	Mental	Behavioral, psychological
N	Neoplasic	Benign, malignant, encapsulated, locally invasive, metastatic
	Nutritional	Deficiencies, excesses, insufficient UVB
I	Infectious	Aerobic bacterial, anaerobic bacterial, chlamydophilial, mycobacterial, mycoplasmal, rickettsial, viral, fungal, parasitic, protozoal, microsporidial
	Ischemic	Vascular, thromboembolic
	Immune-mediated	
	Other inflammatory	Eosinophilic, lymphocytic, plasmacytic, amyloidosis
	Inherited	Coagulation factor deficiencies, enzyme deficiencies, lysosomal storage diseases
	Idiopathic	
	Iatrogenic	Drugs, surgery
T	Toxic	Endogenous, exogenous
	Traumatic	Internal stone formation, external forces

(Gibbons, 2009)

Table 2. Methods of clinical decision making

Intuitive Decisions	Informed Decisions
Unstructured process	Problem-oriented veterinary medicine
Recognize possible course of action Imagine possible outcomes	Consistent, logical, explicit
Difficult to record	Easily recorded
Rapid for experts	Requires effort
Ineffective for novices	Useful for novices and experts
Difficult to defend	Legally defensible
Success varies with circumstances	Success predicted by probability
Learned via emulation of mentors	Learning is structured
Easily biased	Can be unbiased

(Gibbons, 2009)

Figure 1. Problem-oriented veterinary medicine is a cyclical process directed toward identifying a specific diagnosis and implementing effective treatment (Gibbons, 2009).

Progress Notes. A POVMR includes progress notes that describe up-dated SOAPs entered during follow-up evaluations over time. Progress notes allow attending veterinarians to quickly review the status of the case and should include: (1) the goal of management, (2) the clinical signs caused by the problem (S), (3) the status of the patient (getting better, worse, or unchanging) in regard to the problem (S), (4) results of recheck diagnostic tests (O), (5) the basis for the problem statement (A), (6) potential complications for which to monitor (P), and (7) how the problem is to be further investigated (P) (Gibbons, 2009).

A Case Example. An example of a case of cervical spondylopathy (wobbler) in a Doberman would be presented to illustrate a quality problem-orientated record in a veterinary teaching hospital. The dog was presented with hind leg ataxia and hind leg proprioceptive deficits, neck pain and collapsed when the neck is hyperextended. Cervical vertebral body stepping at C_4-C_5, C_5-C_6 and C_6-C_7 was confirmed with plain radiographs. The cervical vertebral bodies intermittent instability causing ventral cervical spinal cord compression was treated with lag-screw fixation and bone grafting. The gait at walk and run was improved post-operatively.

In the follow-up of a series of 125 Dobermans cases, 50 cases were treated conservatively (40%) and 75 cases were treated surgically (60%). At 3 month follow-up, 2 of 43 treated conservatively deteriorated and euthanized (4.0%); while 10 of 75 deteriorated, failed to improved and were euthanized (13.0%) while 87% Dobermans continued to improve. Follow-up examinations at 3 months were subsequently done at 6 months and yearly. Hind limb ataxia, presence or absence of fore limb hypermetria, wearing of toe-nails, proprioceptive deficits of the fore and hind limbs, tonic neck test and neck pain were recorded and scored from 0 to 5. For 44 surgically treated cases, follow-up neck radiography (single neck extended neutral position) was done under anaesthesia 29 cases and 15 cases in the standing position. Grades at initial presentation and the three follow-up periods were compared. Conservatively treated cases almost 30% remained mildly affected (at Grades 1 or 2) for periods in excess of one year, calculated as 1.7 years, while surgically treated as 0.8 years (Rashid-Ibrahim, 1993).

Conclusion

Modern veterinary students learn POVMR (Fig 1) during their clinical training, and many veterinary graduates continue to regularly use the system. Most veterinarians practicing today apply the basic principles as an aide when working through difficult cases.

The POVMR method offers a technique for keeping clear, explicit medical records that are especially important in group, referral, and emergency practices, and for teaching. In addition, POVMR are immensely valuable in practices that employ locum (relief veterinarians) because continuity of case oversight can be provided to clients and patients. Hartung *et al*., (2005) strongly believed that an accurately defined problem list can directly result in thorough, efficient patient care and appropriate treatment.

POVMR is a medical record system by which clinical problems can be effectively diagnosed and treated with hypothetico-deductive reasoning. It is the optimal tool for communication among veterinarians who attend the case and can be defended in a court of law. Adherence to this process of informed decision making helps veterinarians avoid problems inherent in intuitive decision making (Table 2) and works toward meeting the ultimate goals of every case, which are to satisfy the concerns of the client and provide the best possible quality of life for the patient.

References

Gibbons, P.M. (2009). Problem-oriented Exotic Companion Animal Practice. *J. Exotic Pet Medicine* **18**: 181-186.

Hartung, DM, Hunt, J, and Siemienczuk, J., *et al*. (2005). Clinical implications of an accurate problem list on heart failure treatment. *J. Gen. Intern. Med*. **20**: 143-147.

Houston, D.M., Mayhew, I.G., and Radostits, O.M. (2005). Veterinary Medical Records. ***In:*** Radostits O.M., Mayhew, I.G., and Houston, D.M. (Eds.) Veterinary Clinical Examination and Diagnosis. W.B. Saunders. pp. 67-74.

Rashid-Ibrahim, H. (1993). Cervical Spondylopathy in the Dog. Thesis PhD. University of Bristol, England.

Weed, LL. (1968). Medical records that guide and teach. *New England J. Med.* **278**: 593-600.

OLIGODENDROGLIOMA OF THE INTERTHALAMIC : PATHOMORPHOLOGY IN A FRENCH MASTIFF DOG

E. Handharyani[1], H. Huminto[1], A Winarto[2], and K. Ochiai[3]

Laboratories of Pathology[1]and Histology[2],, Faculty of Veterinary Medicine, Bogor Agriculture University – Indonesia; Laboratory of Comparative Pathology[3],, Graduate School of Veterinary Medicine, Hokkaido University – Japan.
Corresponding author : ekowatieko@yahoo.com.hk

Keywords : Oligodendroglioma, interthalamic, pathomorphology, dog.

OAEA 17

Introduction

Both animal and human oligodendrogliomas are known to occur predominantly in the white matter of the cerebral hemispheres (Okazaki *et al*. 1988; Summer *et al*. 1994). It was reported that some brain tumors, including astrocytoma, ependymoma, and central neurocytoma, can occasionally exhibit a honeycomb like appearance (Hasson *et al*. 1982; Uchida *et al*. 1999). Oligodendrogliomas usually unencapsulated, typical appearance of neoplastic cells, and have clear cytoplasm with halo and round nuclei. The present study examined the pathomorphology of oligodendroglioma which occurred in the interthalamic region of the brain and demonstrated that routine staining and immunohistochemistry are definitive method in identifying this tumor.

History

A four and a half-year-old male, French Mastiff dog was introduced to Veterinary Teaching Hospital in a very bad condition. There was no environmental response and all four limbs had myoclonus. The veterinarian gave infusion and corticosteroid therapy, the dog was recovered slowly. Clinical pathology records indicated an increased value of ureum (37 mg/dL) and LED (12 mm/H). Evaluation of creatinine was 0.9 mg/dL. There were no significant changes in the liver functions and other blood sample examinations. One week later the health condition was dropped again, and the condition did not improve after treating. Euthanasia was performed at the owner's request.

Gross, Histopathology and Immunohistochemistry

Grossly, there was increased in the volume of cerebrospinal fluid and moderate level dilation on both lateral ventricles. A small clear mass was found in the interthalamic region. These mass revealed pale and gelatinous, approximately 1.2 x 2 x 1.2 cm in sized, and has narrow hemorrhagic streaks and necrosis. The mass was transparent, soft in consistency, unencapsulated, and has irregular form. On cross section, these tumor ware transparent, soft in palpation, with small number of petechiae in some areas. The heart examination demonstrated that there was thickening of the left atrio-ventricular valves and mild to moderate calcification of myocard. Mild to moderate chronic interstitial nephritis accompanied with multifocal infarction were disseminated diffusely throughout both kidneys. There was no significant lesion found in any other organs.

Tissue samples were fixed in 10% buffered neutral formalin and routinely processed. Paraffin sections were stained with hematoxylin and eosin (HE), and some selected sections of the brain were also stained with Masson's trichrome and Periodic Acid Schiff (PAS). An immunostaining was performed using the Envision polymer method (DAKO Japan Co.Ltd., Kyoto, Japan). The following antibodies were used as primary antibodies; mouse anti-human desmin (Dako Corp., Carpinteria, USA) at a 1 in 10 dilution, mouse anti-swine vimentin (Dako Corp., Glostrup, Denmark) without dilution, and rabbit anti-cow glial fibrillary acidic protein/GFAP (Dako Corp., Denmark) at a 1 in 400 dilution. Primary antibody was omitted in the negative control sections. The immune reaction was evaluated semi-quantitatively as follows: - , no positive cells; +, a small number of positive cells; ++ , a moderate number of positive cells; +++ , many to numerous positive cells.

Histopathological examination revealed that the mass was unencapsulated, infiltrated the surrounding normal tissue. The tumor mass was located in the white matter, at the interthalamic region and consisted of dense sheets of small, round neoplastic cells with a honeycomb structure. These tumor cells usually had round to slightly ovoid, hyperchromatic central nuclei of various sizes and abundant clear cytoplasm with perinuclear halo. Those cells were also had prominent cytoplasmic membranes but do not express cytoplasmic processes. Immunohistochemical evaluation demonstrated that these cells were shown negative immunoreactivities for desmin, vimentin and glial fibrillary acidic protein/GFAP. Several amount of astrocytes which located in peripheral area of the mass showed moderate positive immunoreactivities for GFAP, and some new capillary walls were positive to vimentin.

Discussion and Conclusion

Grossly, the present tumor formed soft gelatinous mass. Histopathologic examination it had mucinous accumulation and a honeycomb appearance formed by the sheets of tumor cells with factually clear cytoplasm and central nuclei. These features represent the typical appearance of oligodendroglioma, similar with previously case that reported by Lendan *et al*., 1998; Nam *et al*., 1999 and Ushida *et al*., 1998. However, the negative immunoreactivities of the tumor cells to desmin, vimentin and GFAP may support our diagnosis. It has been reported that some brain tumors including astrocytoma, ependymoma, or central neuroma can occasionally exhibit honeycomb-like structures (Hasson *et al*., 1982 and Kubota, 1991). Moreover, endothelial proliferation and necrosis were not prominent found in the present tumor. These findings indicate that oligodendroglioma has similar biological characteristics to that of the human form. According to the gross, histopathology and immunohistochemistry evaluations, the present tumor was diagnosed as oligodendroglioma which occurred in the interthalamic region of brain.

References

Hasson J, D Gambarelli, F Grisoli, W Pellet, G Salmon, JF Pellissier and M Toga. 1982. *Acta Neurochir (Wein)* 52: 305-329.

Ide T, K Miyoshi, K Ochiai and N Yasuda. 2009. *Veterinary Pathology* 46: 309-312. Kubota T. 1991. *Pathology Clinical Medicine* 9: 611-619 (in Japanese).

McLendan RE, DS Enterline, RD Tien, WL Thorstad and JM Bruner. 1998. *Tumor of central neuroepithelial origin*. *In*: Russel and Rubinstein`s Pathology of Tumors of the Nervous System, ed., pp. 307-572. Arnold, London, UK.

Nam DH, BK Cho, YM Kim and KC Wang. 1998. *Child`s Nervous System* 14: 127-130.

Okazaki H and BW Scheitthauer. 1988. In: *Atlas of Neuropathology*. Grower Medical Publishing, New York, USA. pp. 57-216.

Summers BA, JF Cummings and A de Lahanta. 1994. In:*Veterinary Neuropathology*. Mosby, St Louis, USA. pp. 351-401.

Uchida K, M Muranaka, T Murakami, R Yamaguchi and S Tateyama. 1999. *Journal of Veterinary Medical Science*. 61 (12): 1323-1326.

Ushida T, H Sonobe, H Mizobuchi, M Toda, T Tani and H Yamamoto. 1998. *Child`s Nervous System* 14: 751-755.

Certificate

The 1st Congress of SEAVSA

Faculty of Veterinary Medicine
Bogor Agricultural University (IPB)

BAYU ROSADI

has attended

The First Congress of SEAVSA

(South East Asia Veterinary School Association)

Animal Health & Production for Better ASEAN Quality of Life

Challenge of Veterinary Education

IPB International Convention Centre
Bogor, Indonesia July 20 - 22, 2010

as

SPEAKER

Assoc. Prof. Dr. Bashir A. F. M.
President of South East Asia Veterinary School Association (SEAVSA)

Dr. I Wayan Teguh Wibawan
Dean of Faculty of Veterinary Medicine
Bogor Agricultural University (IPB) - Indonesia

Deni Noviana, Ph.D
Chairman of Organising Committee
The First Congress of SEAVSA 2010

This scientific congress has the continuing education credits value of 6 (six) points based on IVMA accreditation No.134/CE/S-I/PB-PDHI/VII/2010